

Ultrasound-guided auriculotemporal nerve block for post-herpetic auriculotemporal neuropathy: A case report

¹Sang Hee Im MD PhD, ²Hee Jung Lee MD PhD, ¹Jae Sun Shim MD, ¹Kyunghoon Min, MD

¹Department of Rehabilitation Medicine, CHA Bundang Medical Center, CHA University; ²Department of Dermatology, CHA Bundang Medical Center, CHA University, Gyeonggi-do, Korea

Abstract

Auriculotemporal neuropathy is a rare aetiology of orofacial pain. A 66-year old female patient presented with severe, throbbing pain around the right ear after herpes zoster. The pain was consistent with post-herpetic neuropathy and was not relieved by oral medications. To alleviate neuropathic pain, ultrasound-guided auriculotemporal nerve block was done. The pain was relieved completely and the patient remained symptom-free until the last follow up at eight months after treatment. With understanding of the anatomy and related symptoms of auriculotemporal nerve, auriculotemporal neuropathy can be controlled by ultrasound-guided auriculotemporal nerve block.

Keywords: auriculotemporal nerve block, orofacial pain, post-herpetic auriculotemporal neuropathy, ultrasound

INTRODUCTION

The diagnosis of orofacial pain is a challenge for physicians and the auriculotemporal neuropathy is one of the rare aetiologies which may be considered.¹ The auriculotemporal neuropathy is characterised by paroxysmal attacks of pain around the temporal or auricular region.^{1,2} The frequency of AN was reported to be 0.4% at one tertiary outpatient facility for headache.² The auriculotemporal nerve (ATN) block can be useful in the diagnosis and treatment of pain in these areas.³

We report a successful pain management by ultrasound (US)-guided block of ATN in a patient with orofacial pain having resulted from herpes zoster.

CASE REPORT

A 66-year-old female patient visited the Dermatology clinic for ruptured vesicles and pain around her right ear that developed five days ago. Valaciclovir and gabapentin were prescribed with the diagnosis of herpes zoster. On the next day, because of the symptom aggravation, she was admitted to the Dermatology service. During the five-days of admission, 250 mg of intravenous acyclovir was administered three times a day.

Vesicles around the external auditory canal healed and the pain intensity decreased (7 to 4 in numerical rating scale, NRS).

Twenty weeks after the first visit, severe throbbing, electric-like neuropathic pain occurred on the right ear. Cold wind or light touching in the area triggered her pain attacks. The intensity of throbbing pain occasionally increased to 8 out of 10 in NRS.

She was referred to our clinic to control neuropathic pain in the entire right auricle and its surrounding skin area. We thought that the pain was consistent with post-herpetic neuropathy, defined as pain persisting more than 3 months after the onset of rash in herpes zoster.⁴

Because there was no pain improvement with oral medication, a cervical plexus block was performed targeting right great auricular nerve. 1 week after the block, pain around the auricle improved. However, the pain of the inner ear and tragus did not subside sufficiently.

Based on the temporal and spatial relationship of pain with herpes zoster, neuropathy affecting the trigeminal nerve was the most relevant diagnosis. Oxcarbazepine was tried for one week at a dose of 150 mg per day, but failed.⁵

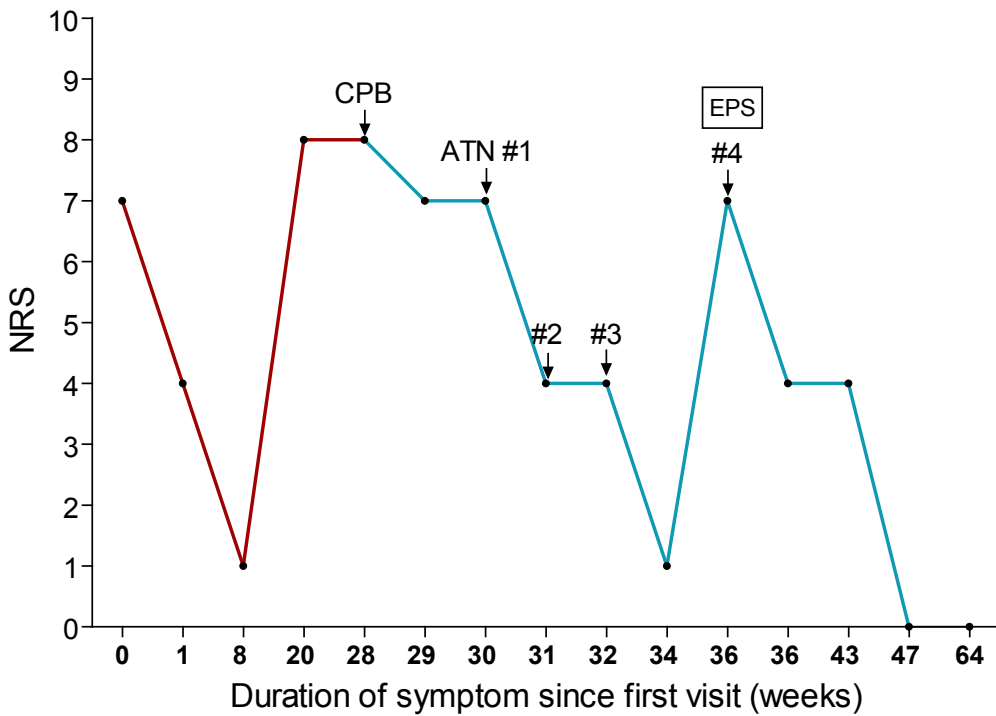
The pain area was localised around the anterior tragus innervated by ATN. The nerve

was blocked under US-guidance for a diagnostic purpose. The intensity of throbbing pain decreased dramatically by half after one week. ATN block was performed twice more weekly. The pain was reduced to 20% of the initial intensity. However, the pain recurred again at 2 weeks after the 3rd block, so we repeated the procedure once again. At this time, electrophysiologic study for trigeminal neuropathy was performed. Results of trigeminal somatosensory evoked potentials, nerve conduction study of facial muscles, blink reflex, and needle electromyography were all within reference ranges.

After the 4th ATN block, the pain remained constantly tolerable and gabapentin was tapered off over 2 months. The patient was followed up at 8 months after the 1st ATN block. She reported no pain, 0 of 10 in NRS and no medication was required (Figure 1).

Technique of injection

The patient is placed in a decubitus position with the right side facing up. The temporomandibular joint is identified after palpitation. A high-frequency linear ultrasound transducer (12-5 MHz, iU 22; Philips, USA) was placed between the tragus and temporomandibular joint (Figure 2). Color Doppler imaging was used to identify the superficial temporal artery (Figure 3). The injection needle was inserted anterior to the tragus posterior to the temporal artery (out-of-plane approach). The reason of out-of-plane approach is that the superficial temporal artery is in the needle trajectory of in-plane procedure during ATN block. 3mL of solution consisting of 0.5% lidocaine 2ml and dexamethasone 1ml (5mg/ml) is slowly injected.



Duration (weeks)	0	1	8	20	28	29	30	31	32	34	36	36	43	47	63	
Gabapentin (mg/day)	900	900		600	600	600	600	600	600	600	100	300	300	100	No	No
Pregabalin (mg/day)			150													
CBZ (mg/day)							150									

Figure 1. Clinical course of the patient. Red and blue lines indicate the treatment duration pre and post-referral for the pain management respectively.

NRS: numerical rating scale, CPB: cervical plexus block, ATN: auriculotemporal nerve, EPS: electrophysiologic study

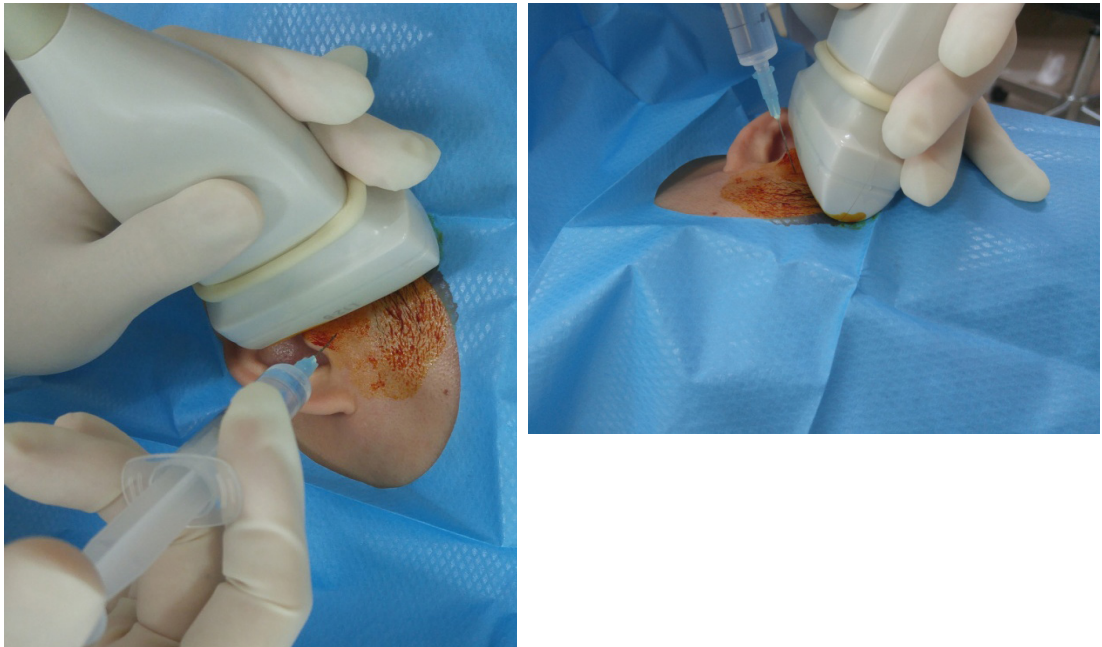

Figure 2. Position of ultrasound transducer and ATN block in out-of-plane.
 ATN: auriculotemporal nerve

DISCUSSION

The landmark-based ATN block is performed anterior to the ear at the level of tragus. Since ATN is close to superficial temporal artery, the artery is the landmark of blind ATN block.⁶

Although the injury of superficial temporal artery during the land-mark based ATN block has not been estimated, US-guided injection technique is currently used to minimise the risk of intravascular injection during various pain interventions.⁷ Aside

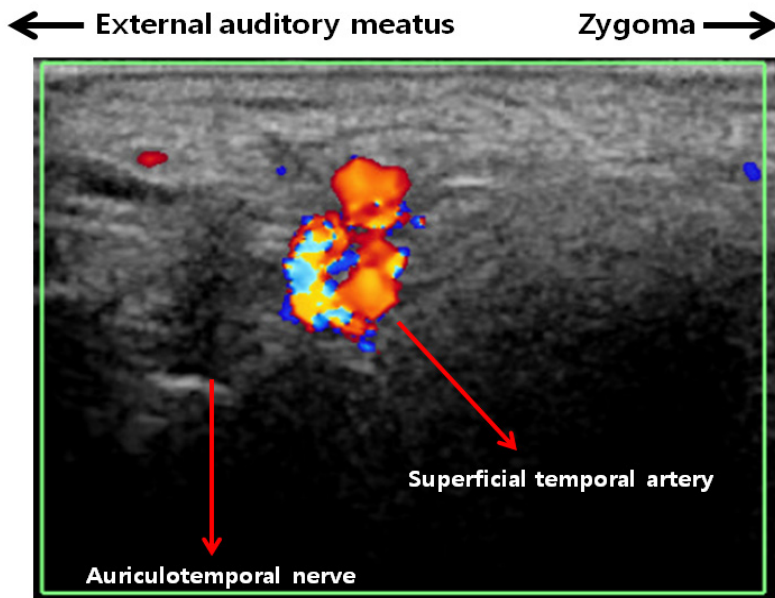


Figure 3. Ultrasound finding of superficial temporal artery and ATN.
 When a linear transducer was placed between tragus and zygoma like Fig. 1, in color doppler imaging, superficial temporal artery was easily identified at the plane. ATN was seen as hypoechoic close to the artery. ATN: auriculotemporal nerve

from the superficial temporal artery, the facial nerve is near the ATN and subsequent facial nerve palsy can occur. The incidence of transient facial nerve palsy after ATN block is reported at 8.6%.⁸

In 2013, the result of US-guided trigeminal nerve block via the pterygopalatine fossa for 15 patients was published and the same group presented a case report of trigeminal neuralgia treated with pulsed radiofrequency through the pterygopalatine fossa in 2015.^{9,10} However, the pterygopalatine approach, where the entry point is anterior to the mandibular condyle, is more proximal than our method.⁹ The blocked area in our method (Figure 3) was the exit area of ATN and the proximal flow of injectate in order to reach the ganglion of trigeminal nerve was not expected.

In one book chapter, US-guided ATN block is introduced and known to be useful in the diagnosis and treatment of painful conditions in areas subserved by the ATN. However, there is no detailed description of treatment process with successful pain control.³

ATN arises from mandibular nerve, the third division of the trigeminal nerve.¹¹ ATN courses upward through the parotid gland and surfaces onto the face from behind the temporomandibular joint. It ascends close to the superficial temporal artery, passing over the posterior portion of the zygoma. The cutaneous branches of ATN provide sensory innervations to the tragus, adjacent auricle of the ear and the posterior part of the temple, and temporomandibular joint.¹² Considering the complex and overlapping innervations of the periauricular area, derived from the ATN, facial, glossopharyngeal, vagus, and 2nd and 3rd cervical nerves, the demonstration of a specific nerve as a cause provoking neuropathy may not be easy around temporomandibular joint.¹³

The pain subsided after the procedure and based on ICHD-II and III, auriculotemporal neuropathy was the most relevant diagnosis. The pain intensity of auriculotemporal neuropathy usually was moderate to severe. With understanding of related anatomy and symptoms, Auriculotemporal neuropathy can be controlled by ultrasound-guided ATN block.

DISCLOSURE

Financial support: None

Conflict of interest: None

REFERENCES

1. Stuginski-Barbosa J, Murayama RA, Conti PC, Speciali JG. Refractory facial pain attributed to auriculotemporal neuralgia. *J Headache Pain* 2012;13(5):415-7.
2. Speciali JG, Goncalves DA. Auriculotemporal neuralgia. *Curr Pain Headache Rep* 2005;9(4):277-80.
3. Waldman SD. Auriculotemporal nerve block. In: Waldman SD, ed: Atlas of interventional pain management. 4th ed. Philadelphia, PA: Saunders, an imprint of Elsevier Inc.; 2015:78-82.
4. Nalamachu S, Morley-Forster P. Diagnosing and managing postherpetic neuralgia. *Drugs Aging* 2012; 29(11):863-9.
5. Cruccu G, Gronseth G, Alksne J, et al. AAN-EFNS guidelines on trigeminal neuralgia management. *Eur J Neurol* 2008; 15(10):1013-28.
6. Bebawy JF, Bilotta F, Koht A. A modified technique for auriculotemporal nerve blockade when performing selective scalp nerve block for craniotomy. *J Neurosurg Anesthesiol* 2014; 26(3):271-2.
7. Soneji N, Peng PW. Ultrasound-guided pain interventions - a review of techniques for peripheral nerves. *Kor J Pain* 2013; 26(2):111-24.
8. McNicholas E, Bilotta F, Titi L, Chandler J, Rosa G, Koht A. Transient facial nerve palsy after auriculotemporal nerve block in awake craniotomy patients. *AA Case Rep* 2014; 2(4):40-3.
9. Nader A, Kendall MC, De Oliveria GS, et al. Ultrasound-guided trigeminal nerve block via the pterygopalatine fossa: an effective treatment for trigeminal neuralgia and atypical facial pain. *Pain Physician* 2013; 16(5):E537-45.
10. Nader A, Bendok BR, Prine JJ, Kendall MC. Ultrasound-guided pulsed radiofrequency application via the pterygopalatine fossa: A practical approach to treat refractory trigeminal neuralgia. *Pain Physician* 2015;18(3):E411-5.
11. Schmidt BL, Pogrel MA, Necoechea M, Kearns G. The distribution of the auriculotemporal nerve around the temporomandibular joint. *Oral Surg Oral Med Oral Pathol Oral Radiol Endod* 1998; 86(2):165-8.
12. Gulekon N, Anil A, Poyraz A, Peker T, Turgut HB, Karakose M. Variations in the anatomy of the auriculotemporal nerve. *Clin Anat* 2005; 18(1):15-22.
13. Olesen J. The international classification of headache disorders, 3rd ed (beta version). http://www.ihs-classification.org/_downloads/mixed/International-Headache-Classification-III-ICHD-III-2013-Beta.pdf.