

# Nonsense mutations of SMC1A gene cause early onset epilepsy limited to females with cluster seizures: response to ketogenic diet add-on therapy

<sup>1</sup>Chunhui Hu, <sup>2</sup>Deying Liu, <sup>3</sup>Kan Xiao, <sup>1</sup>Shuizhen Zhou, <sup>1</sup>Yi Wang, <sup>4</sup>Dan Sun, <sup>4</sup>Zhisheng Liu

<sup>1</sup>Department of Neurology, Children's Hospital of Fudan University, Shanghai; <sup>2</sup>Department of Rheumatology and Immunology, Wuhan Children's hospital, Tongji Medical college, Huazhong University of Science & Technology, Wuhan; <sup>3</sup>Department of Pediatrics, Hubei University of Chinese Medicine, Wuhan; <sup>4</sup>Department of Neurology, Wuhan Children's Hospital, Tongji Medical College, Huazhong University of Science & Technology, Wuhan, China

## Abstract

**Background & Objective:** Nonsense mutations in *SMC1A* have been reported only in females with cluster seizures, all of whom have been described as drug-resistant epilepsy. Here, we aim to explore the use of ketogenic diet treatment. **Methods:** The clinical data of female patients with de novo nonsense mutations in *SMC1A* were collected and analyzed. The clinical data was recruited and analyzed. The peripheral blood of children and their parents was collected. The next generation sequencing was used to find suspected pathogenic mutations and all the confirmed mutations were verified by Sanger sequencing. **Results:** Three patients with heterozygous de novo mutations in *SMC1A* gene were reviewed. All patients were females, presenting with seizure onset at age between 2.5 to 11 months old. One patient had mild developmental delay. One had moderate developmental delay. Another had severe developmental retardation. None of the patients had a clinical diagnosis of Cornelia de Lange syndrome. All three patients had prominent clinical features of cluster seizures. All the nonsense mutations were predicted damaging *SMC1A* protein by PolyPhen-2 HVAR. All the patients were treated with multiple antiepileptic drugs but their seizures remained refractory. When initiated with ketogenic diet, they became seizure free within 3 to 4 weeks.

**Conclusion:** *SMC1A* nonsense mutations can cause early onset epilepsy only in females with cluster seizures. These patients are characterized by drug-resistant epilepsy, but all our three patients have good effect on ketogenic diet add-on therapy.

**Keywords:** *SMC1A*, early onset epilepsy, female with cluster seizures, ketogenic diet

## INTRODUCTION

Epilepsy is a disease of brain defined by at least two unprovoked (or reflex) seizures occurring >24 h apart or one unprovoked (or reflex) seizure and a probability of further seizures similar to the general recurrence risk (at least 60%) after two unprovoked seizures, occurring over the next 10 years, or diagnosis of an epilepsy syndrome.<sup>1</sup> The etiology can be classified as infectious, immune, structural, metabolic, genetic and unknown factors. Genetic etiology has attracted more attention with many gene mutations having been identified in epilepsy. A number of X-linked epilepsies limited to females have been

delineated in which *PCDH19*-related epilepsy is the most common. *SMC1A* pathogenic variants were first described causing Cornelia de Lange syndrome (CdLS), which is characterized by facial dysmorphism, limb anomalies, growth retardation and cognitive impairment. In recent years, females with *SMC1A* truncation mutations were reported exhibiting distinctive features of drug resistant cluster seizures without morphological facial abnormalities of CdLS, which was similar to *PCDH19*-related epilepsy.<sup>2,3</sup> Missense variants of *SMC1A* causing drug-resistant cluster seizures were also reported, despite treatment with various antiepileptic drugs such as valproic

Address correspondence to: Dan Sun, Department of Neurology, Wuhan Children's Hospital, Tongji Medical College, Huazhong University of Science & Technology, Wuhan 430016, China. E-mail: bloveriver@163.com; Yi Wang, Department of Neurology, Children's Hospital of Fudan University, Shanghai 201102, China. E-mail: yiwangshmu@126.com

Date of Submission: 11 September 2020; Date of Acceptance: 27 October 2020



acid, carbamazepine, phenytoin, topiramate, zonisamide, lamotrigine, clobazam, phenobarbital, and levetiracetam.<sup>4</sup> Here, we report three female patients with early onset epilepsy due to nonsense mutation of *SMC1A* presenting with cluster seizures that had good response to ketogenic diet as an add-on therapy.

## METHODS

The clinical data of three affected patients between March 2019 and January 2020 was obtained and analyzed. The peripheral blood samples of these unrelated children and their parents were collected. The next generation sequencing and copy number variation studies of whole exons in family were used to find pathogenic mutations. Sanger sequencing was performed on verifying mutations. PolyPhen-2 analysis was carried out to predict variant effects. The project ethics were approved by our hospital committees.

## RESULTS

### *Patient 1*

The index patient was a 3 years and 1 month girl, being a second-born child from full term pregnancy and natural birth. Both the pregnancy and delivery history of this girl were unremarkable. In her family history, there was no similar disease. Developmental milestone showed that she raised her head at 3 months, sat at 7 months and walked at 19 months. She could not speak until 2 years and 11 months of age. She began having epileptic seizures at 11 months of age, which occurred 3 to 15 times a day and lasted for 3 to 5 days each cluster. The attacks were characterized by loss of consciousness, staring and unilateral limb twitching, sometimes with secondary generalized convulsion lasting for a few minutes. When she was 11 months, she was admitted to our hospital with cluster seizures without any provoking factors. She had severe developmental retardation as determined by Gesell developmental scale. (Table 1). On physical examination, there were no typical Cornelia de Lange syndrome (CdLS) morphological features and she had no other congenital abnormalities. Video-EEG showed frequent multifocal sharp waves, spike waves and spike slow waves. Focal onset seizure was characterized by loss of consciousness, staring eyes and unilateral limb twitching with secondary generalization, lasting for 40 seconds. Ictal EEG showed build up of low amplitude repetitive spike discharges at the occipital and posterior temporal

regions (Figure 1). Her brain MRI was normal. Routine laboratory tests were normal including blood amino acid metabolism screening, urinary organic analysis and chromosome examination. She was given oral levetiracetam (LEV) up to 50 mg/kg/day to treat her seizures. However, she still had cluster seizures up to 5 times per day every time lasting for 2 to 3 days that recur about every 4 to 6 weeks. She transiently became seizure-free for 6 months when oxcarbazepine (OXC) was added. At 1 year and 9 months of age, she had cluster seizures up to 20 times a day lasting for 2 days. We performed family whole exome sequencing and copy number variations studies. We also started her on ketogenic diet (KD) treatment. Four weeks later, her seizures were completely controlled. She remained seizure-free when last follow up at 3 years and 1 month old while on LEV, OXC and KD. However, there was no improvement in her development (Table 1).

### *Patient 2*

The proband was a 1 year and 4 months girl. She was delivered at full term via a cesarean section. The history of pregnancy and delivery for this girl was unremarkable. Her father had one episode of febrile seizure during early childhood. The girl raised her head at 4 months, sat at 8 months, but could still not walk or speak. She began having epileptic seizures at 2.5 months, which occurred 5 times a day and lasted for 2 to 3 days, a total of 5 clusters in 1 month. The seizures started from one leg with secondary generalization lasting for 1 to 2 minutes. She had moderate developmental delay as assessed by Gesell developmental scale (Table 1). When she was 3 months old, she was admitted to her local hospital with a cluster of seizures without any provoking factors. At the local hospital, she was given LEV up to 42 mg/kg/day but she continued to have cluster seizures 5 to 7 times per day, each lasted for 5 to 6 days. Her seizures frequency reduced with topiramate (TPM) but it was stopped because of the side effects of reduced sweating and hyperthermia. Her seizures did not reduce when she was given phenobarbital (PB). When she was 6 months old, she was admitted to our hospital presenting with cluster seizures. On physical examination, she had no morphological and other congenital abnormalities. Video-EEG showed hypersarrhythmia (Figure 2). Routine laboratory tests and brain MRI were normal. There was no significant improvement of her seizure control when OXC was added. Then family whole exome sequencing and copy



**Table 1: Gesell developmental scale scores and developmental age of patients (epilepsy onset age and present age)**

	Patient 1 (11 months old)		Patient 1 (3 years and 1 month old)		Patient 2 (2.5 months old)		Patient 2 (1 year and 4 months old)		Patient 3 (3 months old)		Patient 3 (9 months old)	
GDS domain	DA	DQ	DA	DQ	DA	DQ	DA	DQ	DA	DQ	DA	DQ
Adaption	19w	39.5	10m	27.0	4w	40.0	32w	45.0	8w	57.1	20w	51.2
Motor	18w	37.5	11m	29.7	5w	50.0	34w	47.8	10w	71.4	24w	61.5
Fine motor	16w	33.5	10m	27.0	4w	40.0	30w	42.2	8w	57.1	22w	56.4
Language function	16w	33.5	9m	24.3	4w	40.0	32w	45.0	8w	57.1	20w	51.2
Personal/ social function	18w	33.5	9m	24.3	4w	40.0	28w	40.0	8w	57.1	22w	56.4

GDS= Gesell developmental scale, DA= Developmental age, DQ= Developmental quotient

number variations studies were performed. We started her on KD treatment when she was one year old. She became seizure-free after 3 weeks of KD treatment. At last follow up, she remained seizure-free with LEV, OXC and KD treatment but no improvement in her development (Table 1).

### **Patient 3**

The patient was a 9 months girl second-born from a full term pregnancy and natural birth. The pregnancy history, delivery history and family history of this girl were unremarkable. The girl raised her head at 3 months, sat at 6 months. She started to have epileptic seizures at 3 months old, which occurred 6 times a day and lasted for 2 days. The first seizure type was characterized by loss of consciousness and staring. The second type was unilateral limb jerking lasting for 2 to 3 minutes. Gesell developmental scale scores showed mild developmental delay (Table 1). When she was 3 months old, she was sent to our hospital with cluster seizures without any provoking factors. She had no morphological facial and other congenital abnormalities. Video-EEG showed infrequent sharp and spike waves in the frontal and midline areas on both sides, and a focal seizure was recorded with loss of consciousness and staring lasting for 1 minute. Ictal EEG showed low voltage and rapid bilateral frontal rhythm (Fig 3). Routine laboratory tests and brain MRI were normal. She was given oral LEV up to 45 mg/kg/day. However, she still had cluster seizures 3 to 5 times a day lasting for 2 days and recurred every two days. Her seizures frequency reduced to once a week when OXC was added. We performed family whole exome

sequencing and copy number variations studies. We also started her on KD treatment and she became seizure-free 4 weeks later. At last follow up nine months later, she remained seizure-free while on treatment with LEV, OXC and KD. A second Gesell developmental scale scores was performed showing mild developmental delay (Table 1). (All 3 patients' features were summarized in Table 2)

### *Genetic analysis*

Microarray comparative genome hybridization technology was used to detect the copy number variations and gene next generation sequencing technology was used to analyze family whole exons. Sanger sequencing was performed to verify mutations. Patient 1 revealed a variant of the *SMC1A* gene (c.1495C>T; p.Arg499Ter). Patient 2 revealed a variant of the *SMC1A* gene (c.1489C>T; p.Gln497Ter). Patient 3 showed a variant of the *SMC1A* gene (c.3463C>T; p.Gln1155Ter). Corresponding variants of three patients' parents were normal. All the variants were de novo and predicted damaging by PolyPhen-2 HVAR (Figure 4, Table 3).

### *KD preparation and therapy*

The nutritionist configured KD according to the improved method of Johns Hopkins Hospital. The basic principles are as follows: (1) the calorie is about 75% of the recommended total calories according to the children's age and body weight; (2) all children start KD directly without strict fasting; (3) fluid intake is unrestricted (4) the diet is calculated to have adequate protein and



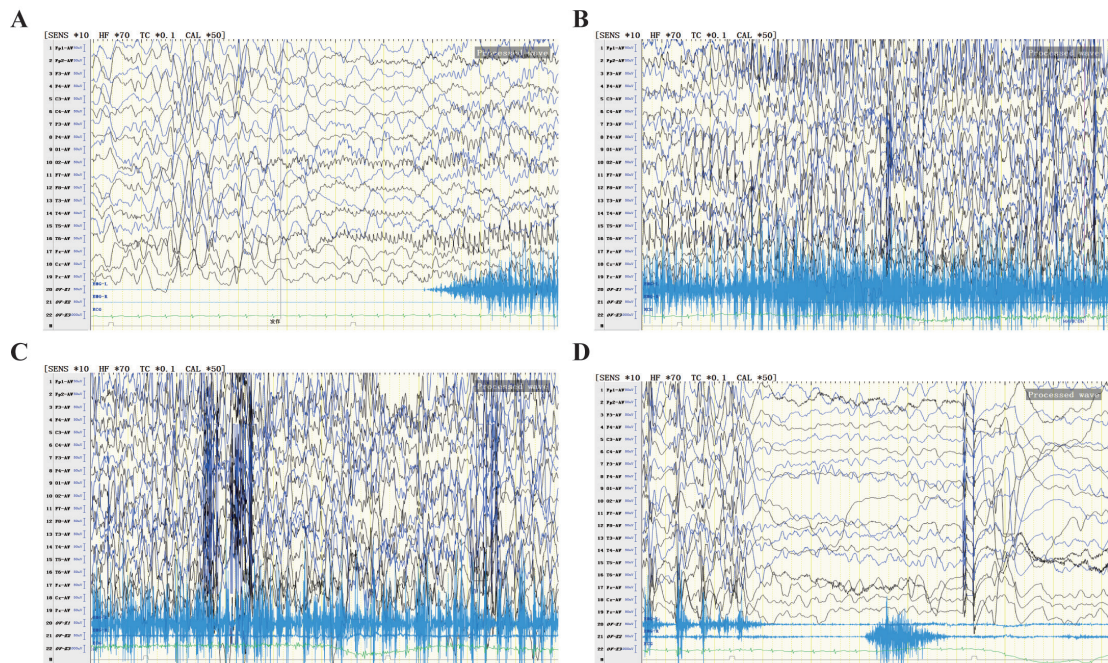


Figure 1. (A) Ictal changes with build of repetitive spike discharges at occipital and posterior temporal regions. (B and C) Secondary generalization. (D) Epileptic seizure stopped.

supplemented with protein, minerals, vitamins and dietary fiber.

All patients were given KD without fasting. The ratio of fat to non-fat starts from 2:1, and increases to 4:1 according to patients' specific conditions within 1-2 months. KD recipe is formulated by using KD catering software suitable for Chinese

dietary habits. The KD proportion is selected according to patients' situation (2.0:1, 2.5:1, 3.0:1, 3.5:1, 4.0:1) to ensure daily protein and calorie requirements. The daily calorie is 251.2-334.9 kJ/kg and protein is 1-2 g/kg. Caloric intake was divided into 4 times a day. At the same time, the vital signs, blood glucose, blood ketone, urine

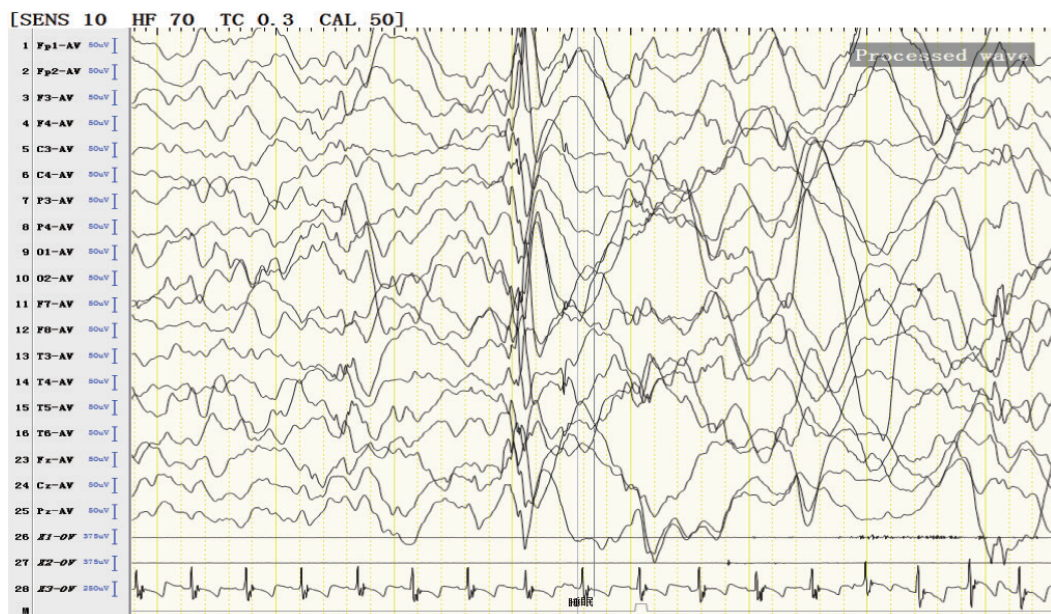


Figure 2. EEG showed hypsarrhythmia.



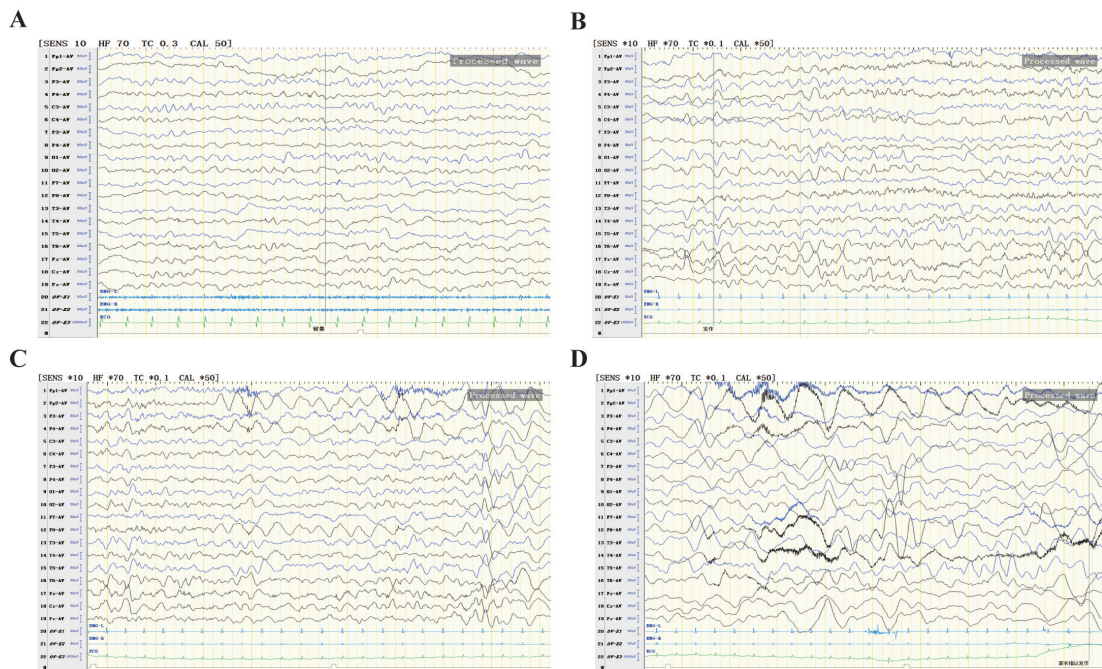


Figure 3. (A) Infrequent sharp and spike waves in the frontal and midline areas on both sides in the interictal EEG. (B and C) EEG shows low voltage and rapid bilateral frontal rhythm. (D) Epileptic seizure stopped.

ketone and related adverse effects were monitored.

During the KD, blood glucose levels were in the normal range. The blood ketone value was between 2.8mmol/L-4mmol/L. No adverse reactions such as nausea, vomiting, diarrhea, constipation, somnolence, hypoglycemia, liver injury, kidney stones and other adverse effects were observed.

## DISCUSSION

*SMC1A* gene (OMIM#300040) locating at Xp11.22 encodes the isoform one protein of 1233 amino acids and one of four core subunits that make up the cohesin ring. The cohesin ring plays an important role in regulating the separation of sister chromatids, DNA repair and facilitating

Table 2: Summary of the phenotypic features in our three cases

	Patient 1	Patient 2	Patient 3
Current age, sex	3 years and 1 month, female	1 years and 4 months, female	9 months, female
Seizure onset	11 months	2.5 months	3 months
Seizure type at onset	FS, cluster seizures, secondary GTCS	FS, cluster seizures, secondary GTCS	FS, cluster seizures
Development retardation	Severe	Moderate	Mild
Malformations	None	None	None
EEG	Frequent multiple and multifocal sharp waves, spike waves and spike slow waves	Hypsarrhythmia	Infrequent sharp and spike waves
Brain MRI	Normal	Normal	Normal
AEDS tried	LEV, OXC	LEV, TPM, PB,OXC	LEV, OXC
Response to KD	Excellent	Excellent	Excellent

Abbreviation: FS=focal seizures; GTCS=generalized tonic-clonic seizures; LEV=levetiracetam; OXC= oxcarbazepine;



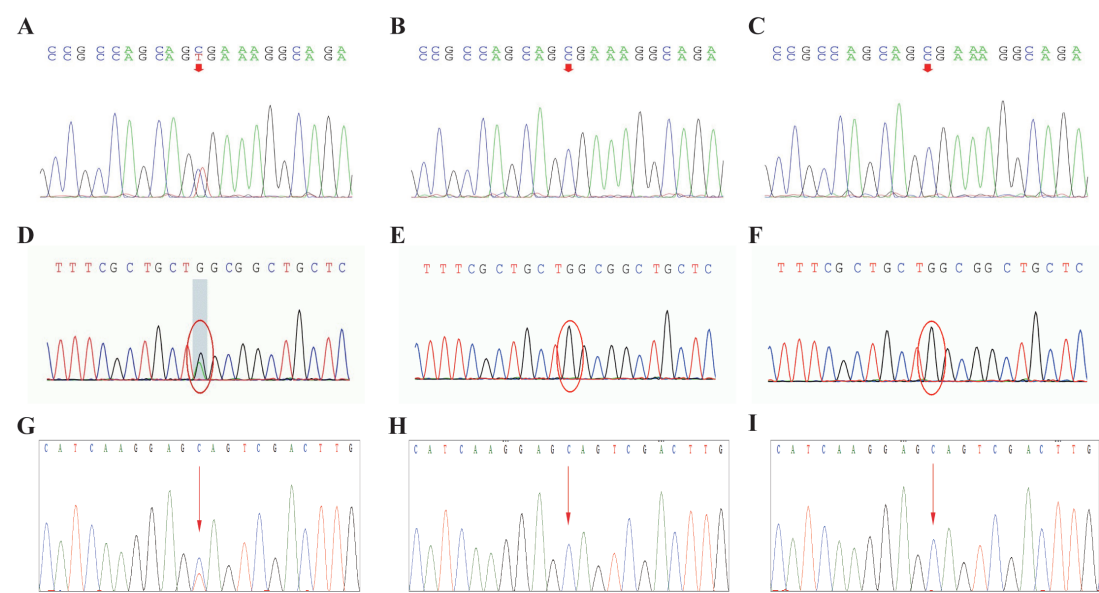


Figure 4. (A) The coding sequence of patient 1, showing a de novo variant of the *SMC1A* gene (c.1495C>T; p.Arg499Ter). (B and C) Corresponding variants of patient one’s parents were normal. (D) The coding sequence of patient 2, showing a de novo variant of the *SMC1A* gene (c.1489C>T; p.Gln497Ter). (E and F) Corresponding variants of patient two’s parents were normal. (G) The coding sequence of patient 3, showing a variant of the *SMC1A* gene (c.3463C>T; p.Gln1155Ter). (H and I) Corresponding variants of patient three’s parents were normal.

spindle attachment onto chromosomes.<sup>5,6</sup> It was reported to partially escape X-inactivation displaying variable phenotype of the allele localized on the inactive X chromosome.<sup>7,8</sup> To date, spectrum of *SMC1A* gene have been reported with CdLS, *SMC1A*-related encephalopathy only with female patients, bladder cancer, leukemia and colorectal carcinomas.<sup>9-14</sup> The *SMC1A* gene neurological spectrum disorders are mainly CdLS and *SMC1A*-related encephalopathy limited to females. Since the *SMC1A* escapes X inactivation, it is probable that the mechanism in female patients with CdLS is due to a dominant negative effect of the altered protein.<sup>15</sup> However, the exact mechanism of CdLS is still unclear. Currently, research show that the clinical phenotype of *SMC1A* variants in patients is not limited to CdLS.<sup>2</sup> It can be associated with moderate to severe neurological impairment and pharmacoresistant epilepsy limited to females. Here, we

preliminarily explored the clinical phenotype and ketogenic diet add-on therapy of *SMC1A*-related early onset epilepsy in females only.

Consistent with previous case reports, our 2 patients have moderate to severe neurological impairment and epilepsy. The seizures usually start at infancy with onset ranging between 4 weeks to 28 months old.<sup>10</sup> The presence of cluster seizures is an obvious characteristic in most cases. Symonds reported seven of 10 cases were noted to have seizure clustering.<sup>10</sup> Oguni showed two cases having seizure clustering, occurring approximately every 2-4 weeks.<sup>4</sup> However, we find the period of seizure clustering ranging from 2 days to several weeks, every time lasting for 2 to 5 days.

Previous reports suggested the feature of EEG was multifocal origin of epileptic seizures based on the combination of both focal and generalized seizures.<sup>10</sup> However, Oguni found

Table 3: Summary of the genetic findings in our three cases

Case	Base change	Amino acid change	Predicted effect on protein	Zygosity	Inheritance
1	c.1495C>T	p.Arg499Ter	Nonsense	Heterozygous	De novo
2	c.1489C>T	p.Gln497Ter	Nonsense	Heterozygous	De novo
3	c.3463C>T	p.Gln1155Ter	Nonsense	Heterozygous	De novo



that the ictal EEG showed frontal-onset and generalized-onset seizures independently.<sup>4</sup> We found that the interictal and ictal EEG findings were poorly correlated with the seizure types in our cases. To our surprise, the EEG of patient 2 though showing hypsarrhythmia, she did not have epileptic spasm. So we further believe that EEG patterns are variable and diverse in this disease. Up to now, more than 104 *SMC1A* variants have been reported in Human diseases.<sup>15</sup> Most of *SMC1A* variants identified in early onset epilepsy is limited to female with cluster seizures patients are missense and nonsense mutations. A minority of missense variants have also been found pathogenic.<sup>4</sup> There is no clear relationship between severity of clinical phenotype and mutation types of truncation/missense variants.

At present, the therapy strategy for the clusters seizure is challenging. Among those patients, most of them are drug-resistant. All our three patients became seizure-free when KD was used as add-on treatment. As known before, oxidative stress produced by an excessive production of free radicals plays an important role in the progress and epileptogenesis of epilepsy. Many studies have shown that neuroprotection or antioxidant compounds exert a positive effect when associated with antiepileptic drugs.<sup>16-19</sup> There is evidence to suggest a relationship between *SMC1A*-mutated CdLS cell lines and oxidative stress. Antioxidant drugs such as ascorbic acid and riboceine can reduce the level of oxidative stress and genomic instability, resulting in a prolonged lifespan of CdLS cells in vitro.<sup>20</sup> KD in children with refractory epilepsy can significantly reduce seizures and improve the clinical symptoms and cognitive function. It also has been demonstrated to improve mitochondrial function and decrease oxidative stress by reducing the production of reactive oxygen species and improving mitochondrial respiration.<sup>21,22</sup> Research in mice and rats have shown that KD improves hippocampal function by activation of an uncoupling protein and increased oxidized glutathione ratio and other antioxidants, possibly by activating transcription of Nrf2.<sup>23</sup> Therefore, we can reasonably speculate that KD add-on treatment reduces seizures by down-regulating the level of oxidative stress when combined with antiepileptic drugs. It can provide us a new approach to the effective treatment in this condition.

The limitations of our study are the small number of patients and the short follow up durations of the cases. Further research should include a larger cohort to validate our

observations. We will continue to study and explore the detailed mechanism between oxidative stress and seizure control. It is also important to address the developmental and intellectual impairments besides seizure control at follow up in this condition.

In conclusion, *SMC1A* mutations can cause early onset epilepsy only in females with cluster seizures. All our three patients had drug-resistant epilepsy but responded well with KD as add-on therapy. We postulate that KD add-on treatment reduces seizures by down-regulating the level of oxidative stress when combined with antiepileptic drugs.

## ACKNOWLEDGEMENT

We would like to express our appreciation to all the patients and their guardians for their participation in this study and our heartfelt gratitude to all team members for their hard work.

## DISCLOSURE

Conflict of interest: None

## REFERENCES

1. Fisher RS, Acevedo C, Arzimanoglou A, *et al.* A practical clinical definition of epilepsy. *Epilepsia* 2014; 55 (4): 475-82.
2. Jansen S, Kleefstra T, Willemsen MH, *et al.* De novo loss-of-function mutations in X-linked *SMC1A* cause severe ID and therapy-resistant epilepsy in females: expanding the phenotypic spectrum. *Clin Genet* 2016; 90 (5): 413-9.
3. Goldstein JH, Tim-Aroon T, Shieh J, *et al.* Novel *SMC1A* frameshift mutations in children with developmental delay and epilepsy. *Eur J Med Genet* 2015; 58 (10): 562-8.
4. Oguni H, Nishikawa A, Sato Y, *et al.* A missense variant of *SMC1A* causes periodic pharmaco-resistant cluster seizures similar to PCDH19-related epilepsy. *Epilepsy Res* 2019; 155: 106149.
5. Mehta GD, Kumar R, Srivastava S, *et al.* Cohesin: Functions beyond sister chromatid cohesion. *FEBS Letters* 2013; 587 (15): 2299-312.
6. Yatskevich S, Rhodes J, Nasmyth K. Organization of chromosomal DNA by SMC complexes. *Ann Rev Genet* 2019; 53: 445-82.
7. Liu JL, Feldman R, Zhang Z, *et al.* *SMC1A* Expression and mechanism of pathogenicity in probands with X-Linked cornelia de Lange syndrome. *Hum Mutat* 2009; 30 (11): 1535-42.
8. Yuen KC, Gerton JL. Taking cohesin and condensin in context. *PLoS Genet* 2018; 14 (1): e1007118.
9. Wenger TL, Chow P, Randle SC, *et al.* Novel findings of left ventricular non-compaction cardiomyopathy, microform cleft lip and poor vision in patient with *SMC1A*-associated Cornelia de Lange syndrome. *Am J Med Genet A* 2017; 173 (2): 414-20.



10. Symonds JD, Joss S, Metcalfe KA, *et al.* Heterozygous truncation mutations of the SMC1A gene cause a severe early onset epilepsy with cluster seizures in females: Detailed phenotyping of 10 new cases. *Epilepsia* 2017; 58 (4): 565-75.
11. Huisman S, Mulder PA, Redeker E, *et al.* Phenotypes and genotypes in individuals with SMC1A variants. *Am J Med Genet A* 2017; 173 (8): 2108-25.
12. Balbás-Martínez C, Sagrera A, Carrillo-de-Santa-Pau E, *et al.* Recurrent inactivation of STAG2 in bladder cancer is not associated with aneuploidy. *Nature Genetics* 2013; 45 (12): 1464-9.
13. Sarogni P, Palumbo O, Servadio A, *et al.* Overexpression of the cohesin-core subunit SMC1A contributes to colorectal cancer development. *J Exp Clin Cancer Res* 2019; 38 (1): 108.
14. Thol F, Bollin R, Gehlhaar M, *et al.* Mutations in the cohesin complex in acute myeloid leukemia clinical and prognostic implications. *Blood* 2014; 123 (6): 914-20.
15. Musio A. The multiple facets of the SMC1A gene. *Gene* 2020; 743: 144612.
16. Méndez-Armenta M, Nava-Ruíz C, Juárez-Rebollar D, *et al.* Oxidative stress associated with neuronal apoptosis in experimental models of epilepsy. *Oxid Med Cell Longev* 2014; 2014: 293689.
17. Puttachary S, Sharma S, Stark S, *et al.* Seizure-induced oxidative stress in temporal lobe epilepsy. *Biomed Res Int* 2015; 2015: 745613.
18. Grewal GK, Kukal S, Kanojia N, *et al.* Effect of oxidative stress on ABC transporters contribution to epilepsy pharmacoresistance. *Molecules* 2017; 22 (3): 365.
19. Geronzi U, Lotti F, Grosso S. Oxidative stress in epilepsy. *Expert Rev Neurother* 2018; 18 (5): 427-34.
20. Cukrov D, Newman TAC, Leask M, *et al.* Antioxidant treatment ameliorates phenotypic features of SMC1A-mutated Cornelia de Lange syndrome in vitro and in vivo. *Hum Mol Genet* 2018; 27 (17): 3002-11.
21. Pinto A, Bonucci A, Maggi E, *et al.* Anti-oxidant and anti-inflammatory activity of ketogenic diet: New perspectives for neuroprotection in Alzheimer's disease. *Antioxidants (Basel)* 2018; 7 (5): 63.
22. Lima PA, Sampaio LPdB, Damasceno NRT. Ketogenic diet in epileptic children: impact on lipoproteins and oxidative stress. *Nutr Neurosci* 2015; 18 (8): 337-44.
23. Milder J, Patel M. Modulation of oxidative stress and mitochondrial function by the ketogenic diet. *Epilepsy Res* 2012; 100 (3): 295-303.