

Indirect traumatic musculocutaneous nerve injury confused with static line injury: A case report

Eun Jin Kim MD, Kyoung-Eun Kim MD

Department of Physical Medicine and Rehabilitation, The Armed Forces Capital Hospital, Gyeonggi-do, South Korea.

Abstract

The musculocutaneous nerve is rarely injured because it is short and is located deep in the shoulder and arm. Damage is usually caused by direct injuries, including stabbing, explosion, and surgery in a war setting. Although indirect injury of the musculocutaneous nerve is extremely rare, it occurs in various situations. In military parachuting-related activities, musculoskeletal injury occurs most commonly, and static line injury is known as rupture of the biceps brachii tendon. However, musculocutaneous neuropathy can also result from secondary injury by the static line. The musculocutaneous nerve goes together with the biceps brachii muscle, and the musculocutaneous nerve could overstretch and compress within the coracobrachialis muscle where the nerve is relatively fixed due to the overloading of the upper arm with shoulder extension. This report focuses on the indirect musculocutaneous nerve injury with axonotmesis following an overloading event by the static line during military parachuting. In this case, some physicians may confuse nerve injury with static line injury, leading to delays in the diagnosis of neuropathy. If the biceps brachii muscle is damaged due to trauma, checking for the accompanying musculocutaneous nerve injury is necessary.

Keywords: Musculocutaneous nerve, electromyography, case report

INTRODUCTION

Musculocutaneous nerve injuries are almost always direct injuries caused by a surgical wound, a bullet, or stabbing.¹ Some authors have described iatrogenic causes, including prolonged positioning of the arm during unrelated surgery²⁻⁴, repetitive, vigorous upper extremity activity (rowing, lifting, or throwing)⁵⁻⁸, or a single forceful extension of the upper extremity (pushing, wrestling, or a traffic accident).⁹⁻¹³

Here, a case of an isolated musculocutaneous nerve lesion with axonotmesis along with a biceps brachii muscle strain due to a static line during military parachuting is reported. Peripheral nerve injuries have been reported to be only 0.3% of parachute-related injuries¹⁴, and no isolated musculocutaneous nerve injury was reported. This case was confused with rupture of the biceps brachii due to static line injury because of a lump on the anterior surface of the middle to distal part of the arm, which is a typical feature of a biceps tendon rupture.

CASE REPORT

A 21-year-old man visited an orthopedic clinic with left shoulder and upper arm pain. He was a marine, and his symptoms had started after military parachuting two months earlier. During parachuting, his shoulder was bent backward, and he lost consciousness for a while after landing. He visited the emergency room on the day of his injury. He complained of left upper arm pain, and physical examination in the emergency room indicated swelling and bruising of that area.

In the orthopedic clinic, physical examination showed that his left elbow joint flexion force had a motor grade of 4/5 on the Medical Research Council scale, and a Popeye sign was observed. Rupture of the biceps brachii tendon was suspected, and the patient was hospitalized for orthopedic surgical treatment.

Ultrasonography demonstrated increased echogenicity in the proximal upper arm level as a result of fatty change in the biceps brachii. Magnetic resonance imaging of the left humerus to establish the surgical operation plan showed an

Address correspondence to: Eun Jin Kim, Department of Physical Medicine and Rehabilitation, The Armed Forces Capital Hospital, Saemaul-ro 177-81, Bundang-gu, Seongnam-si, Gyeonggi-do, 13574 South Korea. Tel: +82-31-7256325, E-mail: jijel95@naver.com

Date of Submission: 24 February 2021; Date of Acceptance: 4 May 2021

<https://doi.org/10.54029/2021ddf>

intermediate signal change in the long and short heads of the biceps brachii (Figure 1).

The patient was referred to the Department of Physical Medicine and Rehabilitation for an electrodiagnostic study because the rupture site was not clearly identified. Physical examination showed that his left elbow flexion was weak, sensation was normal. Motor and sensory nerve conduction studies of both the upper extremities showed no evidence of abnormality (Table 1). Needle electromyography of the left biceps brachii and brachialis muscle indicated abundant abnormal spontaneous activity, with a markedly reduced recruitment pattern on volition (Table 2).

On the basis of the findings of the electrodiagnostic test, musculocutaneous nerve injury was diagnosed, and the scheduled surgery to repair the rupture of the biceps brachii tendon was canceled. Magnetic resonance arthrography was performed in the left shoulder joint due to his shoulder pain and indicated a focal partial-thickness tear of the supraspinatus tendon.

Physical therapy for the shoulder, consisting of range-of-motion exercises and elbow flexor muscle-strengthening exercises, was conducted for two months. The patient subsequently returned to duty.

DISCUSSION

Traumatic rupture of the biceps brachii with upper

arm abrasions by a static line is considered as a classic parachuting injury.¹⁵ The mechanism of static line injury is the entrapment of the static line by an arm upon exiting the aircraft. The static line becomes misrouted under the arm at the time of exit from the aircraft, and this in turn causes blunt trauma to the biceps belly.¹⁶

According to previous case reports, musculocutaneous neuropathy results from shoulder extension by the static line. Several musculocutaneous nerve injuries by overloading that were similar to that in our patient have been reported after a traffic accident,¹¹⁻¹³ but the mechanism of damage is difficult to explain because musculocutaneous nerve injury after a traffic accident is commonly accompanied by other musculoskeletal damage or is surgically treated. Kim *et al.* and Kwon *et al.* theorized that the forearm or the anterior shoulder was severely extended at the time of the accident and that in the coracobrachialis muscle, in which the musculocutaneous nerve was relatively fixed, strong traction force occurred.^{11,13}

In this case, a bruise on the upper arm was caused by overloading of the static line and extension of the shoulder and was accompanied by a rotator cuff injury. The static line apparently impacted the anterior surface of the arm, and the shoulder was strongly extended. Thus, the musculocutaneous nerve was damaged by shoulder extension with straight blunt force on the

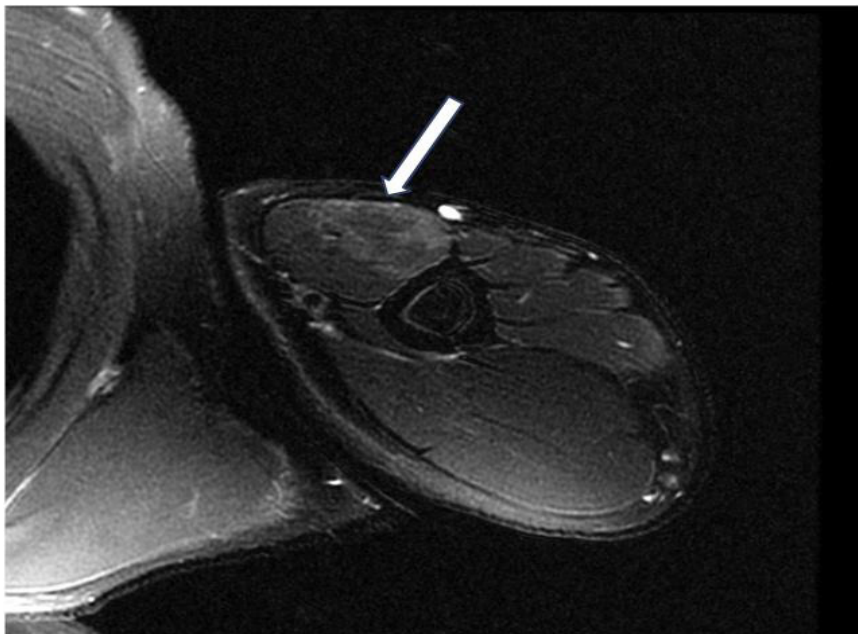


Figure 1: Axial sections of T2-weighted magnetic resonance images of the left humerus. Diffuse intermediate signal intensity is apparent in the short and long heads of the biceps brachii muscles

Table 1: Findings of nerve conduction study

| Nerve | Stimulation site | Latency (ms) | Amplitude (mv) |
|--|------------------|--------------|----------------|
| Musculocutaneous, motor (biceps brachii) | | | |
| Right | Axilla | 2.40 | 12.8 |
| | Erb's point | 2.45 | 12.8 |
| Left | Axilla | 2.60 | 12.2 |
| | Erb's point | 2.60 | 12.3 |
| Lateral antebrachial cutaneous, sensory | | | |
| Left | Forearm | 1.77 | 0.0162 |
| Medial antebrachial cutaneous, sensory | | | |
| Left | Forearm | 1.56 | 0.0214 |

upper arm because the static line was positioned incorrectly at the onset of jumping.

Clinical features of musculocutaneous nerve injury correspond with 2 patterns: proximal injury, resulting in motor and sensory deficit in biceps and the lateral forearm; or distal injury, with primarily sensory deficits. Most of musculocutaneous neuropathy is diagnosed with clinical features and electrodiagnostic study and sensory abnormality is helpful to differential diagnosed from rupture of biceps tendon. His actual injury was confused with rupture of the biceps brachii tendon due to the lump on the anterior surface of the middle to distal part of the arm, which is a typical feature of a biceps tendon rupture. Moreover, military static line parachute jumps seem to be the predominant event that causes a tear of the biceps brachii, and injury of the biceps brachii is therefore easily suspected when pain occurs in the upper arm after parachuting. Another reason for the delay in our patient's diagnosis was that the injury was indirect, and therefore the clinician did not suspect nerve damage from trauma. In our patient, musculocutaneous nerve injury was diagnosed using electromyography 22 weeks after the trauma compared to most trauma-associated nerve injuries diagnosed within three weeks.

After trauma, some physicians may not consider nerve injury, which may lead to

delays in the diagnosis of neuropathy which is confused with other musculoskeletal pathology. Braddom and Wolf reported a weightlifter with musculocutaneous neuropathy who had been misdiagnosed with a biceps tendon rupture, and this error was not discovered until unnecessary surgery revealed the intact tendon.⁶ In this case, it was difficult to diagnose because of the conviction of biceps tendon rupture, such as not evaluating sensory abnormalities initially and delayed electrical diagnosis, but MRI was helpful.

The incidence of military parachute-related injury was reported to be 2.6–50.5 per 1000 jumps, and peripheral nerve injuries were rarely reported.^{17,18} Because of its anatomical location and pathway, the musculocutaneous nerve is easily damaged with the biceps brachii.^{18,19} Additionally, the musculocutaneous nerve is indirectly damaged by the impact on the upper arm, as in our patient. Traumatic rupture of the biceps brachii with upper arm abrasions by the static line were reported in 1.5%–4% of parachuting injuries.^{14,16} Some cases of static line injury were possibly accompanied by musculocutaneous nerve injury.

Musculocutaneous nerve injury is rare but can be caused indirectly by a single episode of vigorous impact in a variety of situations. In our patient, indirect traumatic musculocutaneous nerve injury during military parachuting was

Table 2: Findings of needle electromyography of the left upper extremity

| Examined muscles | Insertional activity | Spontaneous activity | | | Voluntary motor unit action potential (MUAP) | | | |
|------------------|----------------------|----------------------|--------------|-----|--|-----------|-----------------|-------------|
| | | PSW | Fibrillation | CRD | Duration | Amplitude | Polyphasic MUAP | Recruitment |
| Deltoid | Normal | 0 | 0 | 0 | Normal | Normal | Normal | Normal |
| Coracobrachialis | Normal | 0 | 0 | 0 | Normal | Normal | Normal | Normal |
| Biceps brachii | Increased | 3+ | 3+ | 0 | Normal | Normal | Normal | No activity |
| Brachialis | Increased | 2+ | 2+ | 0 | Normal | Normal | Normal | Reduced |

PSW: positive sharp wave; CRD: complex repetitive discharge

diagnosed through the electrodiagnostic test and magnetic resonance imaging. The injury was indirectly caused by straight blunt force on the upper arm by the static line. It was accompanied by a strain of the biceps brachii and thus was confused with rupture of the biceps brachii tendon, which is considered a classic parachuting injury. Clinicians should strongly suspect indirect nerve injury after trauma in order to prevent delayed diagnosis.

REFERENCES

1. Wilbourn AJ. Iatrogenic nerve injuries. *Neurol Clin* 1998; 16(1):55-82.
2. Dundore DE, Delisa JA. Musculocutaneous nerve palsy: An isolated complication of surgery. *Arch Phys Med Rehabil* 1979; 60(3):130-3.
3. Besleaga D, Castellano V, Lutz C, Feinberg JH. Musculocutaneous neuropathy: Case report and discussion. *HSSJ* 2010; 6(1):112-6.
4. Özyuvaci E, Şitilci AT, Wadhwa A. Musculocutaneous neuropathy after anaesthesia for thyroid surgery: A case report. *Agri* 2012; 24(2):93-5.
5. Mastaglia FL. Musculocutaneous neuropathy after strenuous physical activity. *Med J Aust* 1986; 145:153-4.
6. Braddom RL, Wolfe C. Musculocutaneous nerve injury after heavy exercise. *Arch Phys Med Rehabil* 1978; 59(6):290-3.
7. Hsu JC, Paletta GA, Gambardella RA, Jobe FW. Musculocutaneous nerve injury in major league baseball pitchers: A report of 2 cases. *Am J Sports Med* 2007; 35(6):1003-6.
8. Stephens L, Kinderknecht JJ, Wen DY. Musculocutaneous nerve injury in a high school pitcher. *Clin J Sport Med* 2014; 24(6):e68-9.
9. Fattal C, Weber J, Beuret-Blanquart F. Isolated musculocutaneous nerve palsy in spinal cord injury. *Spinal Cord* 1998; 36(8):591-2.
10. Chabra T, Tahbaldar P. Case report on isolated musculocutaneous nerve injury following a wrestling match. *IOSR JDMS* 2015; 14(3):97-9.
11. Kwon SY, Han EY, Min KH, Im SH. Isolated musculocutaneous nerve injury following a pedestrian-automobile collision: A case report. *Neurol Asia* 2019; 24(3):267-70.
12. Kim DH, Lim SI, Kil EY. An isolated musculocutaneous nerve palsy. *J Korean Acad Rehabil Med* 2000; 24(4):799-802.
13. Kim Yu-soo, Kang Bo-sung et al. A case of isolated musculocutaneous nerve injury following motorcycle accident. *J Korean Assoc EMG Electrodiagn Med* 2005; 7(2):128-33.
14. Parachuting injury surveillance, Fort Bragg, North Carolina, May 1993 to December 1994. *Craig SC Milit Med* 1997 162(3):162-4.
15. Bricknell MC, Craig SC. Military parachuting injuries: A literature review. *Occup Med (Lond)* 1999; 49(1):17-26.
16. Wilson DJ, Parada SA, Slevin JM, Arrington ED. Intrasubstance ruptures of the biceps brachii: Diagnosis and management. *Orthopedics* 2011; 34(11):890-6.
17. Guo WJ, Liu XS, Chen YR, Zhou JQ. Military parachuting injuries among male and female cadet pilots: A prospective study of 59,932 jumps. *Applied Mechanics and Materials* 2014; 590:837-41.
18. Dumitru D, Zwarts MJ. Brachial plexopathies and proximal mononeuropathies. In: Dumitru D, Amato AA, Zwarts MJ, eds: *Eletrodiagnostic medicine*, 2nd ed, Philadelphia: Hanley & Belfus, Inc., 2002:809-10.
19. Yilmaz C, Eskandari MM, Colak M. Traumatic musculocutaneous neuropathy: A case report. *Arch Orthop Trauma Surg* 2005; 125(6):414-6.