

# Is increased intracranial pressure a reason for headache in COVID-19 patients? Evaluation with optic nerve sheath diameter

<sup>1</sup>Zuhal Ozer Simsek, <sup>1</sup>Seda Guzeldag, <sup>2</sup>Sule Ketenci Ertas, <sup>3</sup>Yasemin Dincaslan

<sup>1</sup>Department of Intensive Care Unit, <sup>2</sup>Rheumatology, Department of Internal medicine, <sup>3</sup>Department of Radiodiagnostic, Kayseri Training and Research Hospital, Kayseri, Turkey

## Abstract

**Objective:** Headache occurs in 10-15% of COVID-19 patients. The optic nerve sheath diameter (ONSD) is an indirect measurement of the intracranial pressure (ICP). This study aimed to determine whether there was a relationship between ICP and headache in COVID-19 patients by measuring the ONSD. **Methods:** The study included a total of 91 people: 68 COVID-19 patients and 23 healthy volunteers as a control group. The two groups were first compared in terms of the ONSD using the ultrasonography (US) technique. Second, the severity of headache in the COVID-19 group was numerically evaluated (from 0 to 10) and the group was then divided into low, moderate, and high subgroups according to headache severity. Afterwards, the ONSD measurements of participants in the COVID-19 group were compared in between the subgroups. **Results:** We found that the COVID-19 patients had higher ONSD levels than healthy controls ( $4.7\pm 0.7$  mm vs.  $4.1\pm 0.4$  mm,  $p < 0.001$ ). In the COVID-19 patients, there was a significant difference of ONSD levels between the low and moderate as well as the low and high groups. However, no significant difference was observed between the moderate and high groups. There was also a positive correlation between the headache intensity and ONSD diameter level ( $p=0.01$   $r=0.39$ ).

**Conclusion:** COVID-19 patients with headache had higher ONSD levels than healthy volunteers, consistent with increased intracranial pressure. The latter may be one of the causes of headache in COVID-19.

**Keywords:** COVID-19, headache, optic nerve

## INTRODUCTION

Beginning in Wuhan in early January 2020, severe acute respiratory syndrome coronavirus (SARS-CoV)-2 caused a pneumonia epidemic that has affected the entire world.<sup>1</sup> Like other coronaviruses, SARS-CoV-2 infections mainly cause flu-like symptoms such as fever, cough, and fatigue.<sup>2</sup> However, headache may be the main symptom in some cases. Headaches occur in around 12.5% of COVID-19 patients though this prevalence varies in different studies.<sup>3</sup> The most notable feature of COVID-19-related headache is that it starts suddenly and progresses gradually. Also, patients usually seek care in the acute phase.<sup>4</sup> Headache is one of the clinical reflections of increased intracranial pressure.<sup>5</sup> The etiology of COVID-19-related headache is unclear, but increased intracranial pressure may be one of

the possible mechanisms. Evaluation of ICP is critical in many neurological and neurosurgical disorders. Clinical symptoms of elevated ICP such as headache, changes in consciousness, and vomiting, are considered non-specific indicators of this condition.<sup>6</sup> A wide variety of noninvasive methods have been developed to objectively measure intracranial pressure, including non-invasive ultrasonographic ONSD measurement.<sup>7</sup> Increased ICP affects the sheath of the optic nerve, which connects to the subarachnoid compartment, causing widening of the sheath and increasing its diameter.<sup>8</sup> Many studies have demonstrated a correlation between millimetric changes in optic nerve diameter and increased intracranial pressure.<sup>9</sup> Though research has not established an exact upper limit for ONSD indicating ICP<sup>10</sup>, studies have shown that ONSD does not differ

*Address correspondence to:* Zuhal Ozer Simsek, Kayseri Kayseri Training and Research Hospital, Şeker Mah. Molu Cad. No:1, 38010 Kayseri/Turkey. Tel.:+90 352 0 352 315 77 00 E-mail: drzosimsek@gmail.com

Date of Submission: 5 August 2021; Date of Acceptance: 16 February 2022

<https://doi.org/10.54029/2022ynr>

according to gender.<sup>11,12</sup> This study aimed to investigate whether intracerebral pressure is increased in patients with COVID-19 with a headache by measuring the ONSD.

## METHODS

We planned a prospective observational study in a tertiary hospital. The study included patients admitted to the outpatient clinic with suspected COVID-19 and who subsequently had the diagnosis confirmed with real-time PCR. A total of 91 people, 68 in the patient group and 23 in the control group (healthy volunteers with similar demographic features) were evaluated using US. First, ONSD levels were compared between the two groups (i.e. the COVID-19 group and the control group). Then the COVID-19 group was divided into three subgroups (low, moderate, and high) according to intensity of headache levels reported by subjects on a numeric rating scale (NRS).<sup>13</sup> The headache was categorised as low intensity (1 to 3), moderate intensity (4 to 6), or high intensity (7 to 10) on the NRS.

We obtained approval from the local ethics committee as well as informed consent from each subject.

Patients were included in the study if they had active COVID-19 without any disease that increased intracranial pressure or affected optic nerve diameter measurement. Patients were excluded if they had a history of trauma, were younger than 18 years of age, had morbid obesity (body mass index (BMI) > 40 kg/m<sup>2</sup>), were pregnant, or had a history of glaucoma or ophthalmic disease. Also excluded were individuals with ocular prostheses, patients with neurological diseases that increased intracranial pressure, and patients with end-stage renal and hepatic insufficiency. Finally, we excluded patients with a history of headaches, such as migraines and tension-type headaches.

### *Ultrasonography technique*

During the study period, the same radiologist performed blinded ONSD measurements for each patient, using the L12-4 linear probe of the Philips Clear-Vue Ultrasound device for evaluation. The participants were in the supine position, and their heads were elevated about 30 degrees. The probe was performed in the superior-outer temporal part of the upper eyelid. In accordance with the literature<sup>14-16</sup>, ONSD measurements were made 3 mm below the papillae perpendicular to the eyeball. Ultrasound gel was used on the surface

of each eyelid, and the evaluations were made in the axial and sagittal planes of the widest diameter visible, 3 mm behind the retina in both eyes. Six measurements were taken from each patient, three times for the right eye and three times for the left eye.

### *Statistical analysis*

The distribution model of the data was determined using the Shapiro-Wilk test. T-tests for independent samples and Mann-Whitney U tests were used to compare means in groups with normal and non-normal distributions respectively. Pearson Chi-square and Fisher's exact tests were used to compare categorical data. SPSS Statistics Version 21.0 (IBM Corp., USA) was used for all statistical analyses. Correlation analysis was performed by Pearson's and Spearman's analyses for parametric and nonparametric variables respectively. Values were expressed as means  $\pm$  standard deviations or medians as appropriate. A probability value of  $p < 0.05$  was considered significant.

## RESULTS

Ninety-one subjects were recruited: 68 patients in the study group and 23 healthy controls. Five hundred forty-six measurements of ONSD were done. Age and BMI values were similar for the two groups. Demographic findings are demonstrated in Table 1. The COVID-19 group had a significantly higher OSND diameter than the healthy controls ( $p < 0.001$ ).

The COVID-19 group was evaluated in terms of ONSD and headache intensity on NRS (Figure 1). There was a statistically significant difference among COVID-19 subgroups ( $p = 0.01$ ). Pairwise comparison of the COVID-19 subgroups (Table 2), found a significant difference in the OSND between the low and moderate intensity groups as well as the low and high intensity groups, but no significant difference between the moderate and high intensity groups. The highest ONSD values were detected in the moderate intensity group. A significant positive correlation was found between headache score and ONSD diameter ( $p = 0.01$ ,  $r = 0.39$ ). No correlation was found between ONSD and serum glucose, Na, K, or BMI ( $p > 0.05$ ). OSNDs were not significantly different between female and male COVID-19 patients. ( $4.3 \pm 0.4$ ,  $4.7 \pm 0.9$  respectively,  $p > 0.05$ ).

## DISCUSSION

COVID-19 patients with headache had

**Table 1: Demographic data of participants**

	Patient Group (n=68)	Control Group (n=23)	p-value
Age (year)	56.1±15.7	52.1±15.9	0.25
Sex ( male-female)	28F- 40M	17F-5M	0.03
BMI (kg/m <sup>2</sup> )	27.1±5.0	21.3±3.1	0.26
Na (136-145 mmol/L)	137.7±3.6	136.0±2.4	0.15
K (3.5-5.1 mmol/L )	4.2±0.47	4.3±0.3	0.3
Glucose (70-110 mg/dL)	119.9±29.7	102.2±16.9	0.02
ONSD (mm)	4.7±0.7	4.1±0.4	<0.001

significantly higher ONSD levels than healthy controls. Interestingly, however, the group with moderate intensity headache had a wider ONSD than the group with high intensity headache. We attributed this result to chance because of a small number of patients in the group with high intensity headache.

COVID-19 often presents with symptoms of fever, cold, sore throat, diarrhea, and respiratory failure<sup>17</sup>. However, it may also present with neurological symptoms such as headache, dizziness, seizures, anosmia, paralysis, and impaired consciousness.<sup>18</sup> In a meta-analysis that included a total of 13,480 COVID-19 patients, approximately 10% of patients complained of severe headache or dizziness.<sup>3</sup> There are many possible reasons for headache in COVID-19. One of them is increased intracranial pressure.<sup>5</sup>

The signs of increased intracranial pressure are well known but not specific. Invasive techniques such as insertion of intraventricular catheters, intracranial pressure transducers, subarachnoid bolts, and epidural transducers as well as noninvasive methods such as transcranial doppler ultrasound and ONSD can be used to measure ICP.<sup>19,20</sup>

The diameter of ONSD has been found to be between 3.7 mm and 5.0 mm in healthy individuals.<sup>21,22</sup> In our study, the ONSD diameter was as 4.1±0.4 mm in healthy controls, comparable to that found in previous studies. In studies related to increased ONSD due to ICP, an upper limit of 4.8 mm and 5.9 mm has been found to have a sensitivity of 74% and 96% and specificity of 74 and 100%, respectively for raised ICP.<sup>15,23</sup>

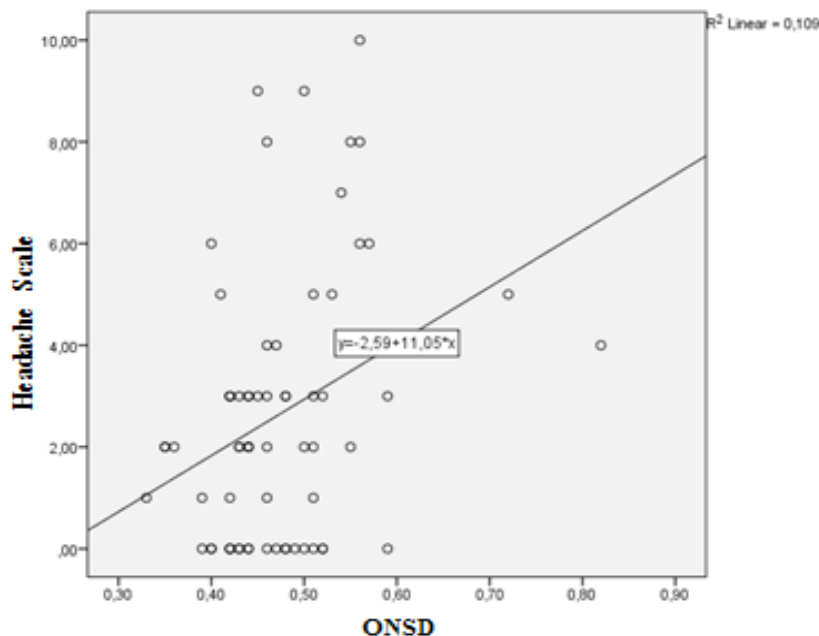


Figure 1. This diagram reflects changes of the ONSD (Optic nerve sheath diameter) and headache intensity on NRS of the patients.

**Table 2: Relationship between headache intensity and ONSD in the COVID-19 group**

Headache Score (0-10)	ONSD (mm)
Low (1-3) (n=36)	4.4 ±0.5
Moderate (4-6) (n=25)	5.4±1.2
High (7-10) (n=7)	5.1±0.4

Our study found ONSD levels in the moderate and high intensity groups to be  $5.4 \pm 1.2$  mm and  $5.1 \pm 0.4$  mm, respectively. These values are consistent with increased ICP, and suggest that raised ICP is present in COVID-19 patients with headache. In our study, ONSD in COVID-19 patients with only low intensity headache were not significantly different from normal values. Additionally a significant positive correlation was found between headache score and ONSD ( $p = 0.01$   $r = 0.39$ ).

There are some limitations in our study. First, the study group number was relatively small. Second, the relationship between ONSD and headache over time was not examined.

In conclusion, we found that ONSD values were increased in COVID-19 patients with headache. Moreover, there was a positive correlation between headache severity and ONSD. Prospective studies with more participants are needed for routine use of ONSD and its correlation with headache severity.

## DISCLOSURE

Financial support: None.

Conflict of interest: None

## REFERENCES

1. Remuzzi A, Remuzzi G. COVID-19 and Italy: what next? *Lancet* 2020; 395:1225-8. doi: 10.1016/S0140-6736(20)30627-9.
2. Wu D, Wu T, Liu Q, *et al.* The SARS-CoV-2 outbreak: What we know. *Int J Infect Dis* 2020; 94:44-8. doi: 10.1016/j.ijid.2020.03.004.
3. Yassin A, Nawaiseh M, Shaban A, *et al.* Neurological manifestations and complications of coronavirus disease 2019 (COVID-19): a systematic review and meta-analysis. *BMC Neurol* 2021; 21:138. doi: 10.1186/s12883-021-02161-4.
4. Bolay H, Gul A, Baykan B. COVID-19 is a real headache! *Headache* 2020; 60:1415-21. doi: 10.1111/head.13856.
5. Canakci Y, Koksall O, Durak VA. The value of bedside ocular ultrasound assessment of optic nerve sheath diameter in the detection of increased intracranial pressure in patients presenting to the emergency room with headache. *Niger J Clin Pract* 2018; 21:778-82. doi: 10.4103/njcp.njcp\_119\_17.
6. Czosnyka M, Pickard JD. Monitoring and interpretation of intracranial pressure. *J Neurol Neurosurg Psychiatry* 2004; 75:813-21. doi: 10.1136/jnnp.2003.033126.
7. Kristiansson H, Nissborg E, Bartek J, Jr., *et al.* Measuring elevated intracranial pressure through noninvasive methods: a review of the literature. *J Neurosurg Anesthesiol* 2013; 25:372-85. doi: 10.1097/ANA.0b013e31829795ce.
8. Hansen HC, Helmke K. The subarachnoid space surrounding the optic nerves. An ultrasound study of the optic nerve sheath. *Surg Radiol Anat* 1996; 18:323-8.
9. Robba C, Cardim D, Tajsic T, *et al.* Ultrasound noninvasive measurement of intracranial pressure in neurointensive care: A prospective observational study. *PLoS Med* 2017; 14:e1002356. doi: 10.1007/BF01627611.
10. Strumwasser A, Kwan RO, Yeung L, *et al.* Sonographic optic nerve sheath diameter as an estimate of intracranial pressure in adult trauma. *J Surg Res* 2011; 170:265-271. doi: 10.1016/j.jss.2011.03.009.
11. Knight OJ, Girkin CA, Budenz DL, Durbin MK, Feuer WJ. Effect of race, age, and axial length on optic nerve head parameters and retinal nerve fiber layer thickness measured by Cirrus HD-OCT. *Arch Ophthalmol* 2012; 130: 312-8. doi: 10.1001/archophthalmol.2011.1576.
12. Rao HL, Kumar AU, Babu JG, Kumar A, Senthil S, Garudadri CS. Predictors of normal optic nerve head, retinal nerve fiber layer, and macular parameters measured by spectral domain optical coherence tomography. *Invest Ophthalmol Vis Sci* 2011; 52:1103-10. doi: 10.1167/iovs.10-5997.
13. Hong CK, Joo JY, Shim YS, *et al.* The course of headache in patients with middle-to-high headache due to low traumatic brain injury: a retrospective cross-sectional study. *J Headache Pain* 2017; 18:48. doi: 10.1186/s10194-017-0755-9.
14. Dubourg J, Javouhey E, Geeraerts T, *et al.* Ultrasonography of optic nerve sheath diameter for detection of raised intracranial pressure: a systematic review and meta-analysis. *Intensive Care Med* 2011; 37:1059-68. doi: 10.1007/s00134-011-2224-2.
15. Kimberly HH, Shah S, Marill K, *et al.* Correlation of optic nerve sheath diameter with direct measurement of intracranial pressure. *Acad Emerg Med* 2008; 15:201-4. doi: 10.1111/j.1553-2712.2007.00031.x.
16. Guzeldag S, Yilmaz G, Tuna M, *et al.* Measuring the optic nerve sheath diameter with ultrasound in acute middle cerebral artery stroke patients. *J Stroke Cerebrovasc Dis* 2021; 30:105523. doi: 10.1016/j.jstrokecerebrovasdis.2020.105523.
17. Guan WJ, Ni ZY, Hu Y, *et al.* Clinical characteristics of coronavirus disease 2019 in China. *N Engl J Med* 2020; 382:1708-20. doi: 10.1056/NEJMoa2002032.
18. Jiang F, Deng L, Zhang L, *et al.* Review of the clinical characteristics of coronavirus disease 2019 (COVID-19). *J Gen Intern Med* 2020; 35:1545-9. doi: 10.1056/NEJMoa2002032.
19. Rangel-Castillo L, Robertson CS. Management

- of intracranial hypertension. *Crit Care Clin* 2006; 22:713-32; abstract ix. doi: 10.1016/j.ccc.2006.06.003.
20. Singhi SC, Tiwari L. Management of intracranial hypertension. *Indian J Pediatr* 2009; 76:519-29. doi: 10.1007/s12098-009-0137-7
  21. Govil D, Srinivasan S. Optic nerve sheath diameter measurement using bedside ultrasound: Is it accurate? *Indian J Crit Care Med* 2015; 19:443-445, doi: 10.4103/0972-5229.162456.
  22. Maude RR, Hossain MA, Hassan MU, *et al.* Transorbital sonographic evaluation of normal optic nerve sheath diameter in healthy volunteers in Bangladesh. *PLoS One* 2013; 8:e81013. doi: 10.1371/journal.pone.0081013.
  23. Geeraerts T, Launey Y, Martin L, *et al.* Ultrasonography of the optic nerve sheath may be useful for detecting raised intracranial pressure after high brain injury. *Intensive Care Med* 2007; 33:1704-11. doi: 10.1007/s00134-007-0797-6.