

# Use of repetitive transcranial magnetic stimulation and 2D ultrasound in resection of low-grade glioma at motor strip area in resource limited setting

<sup>1</sup>Sushanta Sahoo, <sup>2</sup>Sujita Kar, <sup>3</sup>Chhitij Srivastava

<sup>1</sup>Department of Neurosurgery, PGIMER, Chandigarh; <sup>2</sup>Department of Psychiatry, KGMU, Lucknow; <sup>3</sup>Department of Neurosurgery, KGMU, Lucknow, INDIA

## Abstract

Eloquent area glioma surgery is technically demanding. Identification and preservation of the functional area determines the long term outcome. Here we discuss the use of transcranial magnetic stimulation (TMS) and 2D ultrasound (2DUSG) in resection of low grade glioma (LGG) located at motor strip area. In five patients where the LGG was located close to motor area were evaluated with TMS in the preoperative period and the functional area is marked. This information is used for planning the craniotomy. A 2DUSG is used to detect the margin of resection. Complete excision was feasible in two and partial resection in three without any added deficit. TMS is an useful tool for localizing motor area in the pre operative period for patients with tumor located close to the motor area. Additionally 2DUSG provides real time imaging to safeguard the eloquent brain area. Combination of these two offers low cost, easily available method for resecting eloquent area brain tumors in resource limited areas.

*Keywords:* Eloquent area; low grade glioma; transcranial magnetic stimulation; ultrasound

## INTRODUCTION

Glioma surgery located near the motor strip area is demanding. Maximal tumor resection with functional preservation requires identification of eloquent areas in the pre and intra operative period. Several modalities such as magnetic resonance imaging with functional mapping, diffusion tensor imaging, intra operative use of direct electrical stimulation, neuronavigation are being used to assess the eloquent areas adjacent to the tumor. However, such modalities may not be available in resource limited settings.<sup>1,2</sup> Here, we discuss the use of repetitive transcranial magnetic stimulation (TMS) in preoperative localization of motor area and 2D ultrasound to assess the extent of tumor resection in cases of low grade glioma at motor area.

## RESULTS

Five patients operated for gliomas located at the motor area were selected for pre operative localization of the motor area with the use of TMS (Table 1). There were four males and one female with an average age of 45.6 years. All of

these patients presented with headache and focal seizure. At presentation all were conscious, alert without any focal neurological deficit. On MRI three had left posterior frontal intraparenchymal lesion suggestive of low grade glioma (LGG) and in two LGG were on right posterior frontal area close to the motor strip.

Radiologically the central sulcus was identified on the side of tumor in three patients and was effaced in two. TMS was used for localization of the motor strip and resting motor threshold. Using a figure of eight angular coil, with single pulse TMS, hand area of the bilateral motor cortex was localized by using the standard five centimeter localization method in the preoperative period in all of them and the hand area was marked on both the sides (Table 1). The average difference between the hand areas on right and left sides was 0.9cm. In three patients the lesion was anterior to the motor area and in two it was posterior. In all patients the incision was marked for craniotomy safeguarding the marked hand area (Figure 1A, B). Patients were operated under general anesthesia. The extent of tumor resection was guided by 2D ultrasound. In all patients resection cavity

Address correspondence to: Dr. Sushanta Kumar Sahoo, Dept. of Neurosurgery, PGIMER, Chandigarh, India. Tel: +91-9416358829, email: drsushantsahoo@gmail.com

Date of Submission: 9 April 2023; Date of Acceptance: 17 June 2023

<https://doi.org/10.54029/2023wrw>

**Table 1: Clinical, radiological and TMS parameters of patients operated for eloquent area glioma**

Patient Age in years/ Sex	Radiological diagnosis	RTMS Parameters	Difference (between right and left) in the motor area marked on TMS	Relation of tumor with motor area	Post operative deficit	Extent of resection
38/M	Left perirolandic LGG	Nasion-inion – 35 cm Head circumference – 52 cm Inter tragus – 55 cm Amplitude – right 30, Left 32	Both at same line	Anterior	No	Gross total
49/M	Right perirolandic LGG	Nasion-inion – 38 cm Head circumference – 58 cm Inter tragus – 52 cm Amplitude – right 33, Left 32	1.5cm	Posterior	No	Sub total
33/F	Left perirolandic LGG	Nasion-inion – 32 cm Head circumference – 50 cm Inter tragus – 48 cm Amplitude – right 38, Left 40	1.8cm	Anterior	No	Sub total
56/M	Left perirolandic LGG	Nasion-inion – 33 cm Head circumference – 51 cm Inter tragus – 54 cm Amplitude – right 40, Left 38	0.4cm	Anterior	No	Sub total
52/M	Right perirolandic LGG	Nasion-inion – 31 cm Head circumference – 52 cm Inter tragus – 54 cm Amplitude – right 27, Left 31	0.8cm	Posterior	No	Gross total

LGG: Low grade glioma, TMS : Trans cranial magnetic stimulation

is filled with air and saline mixture and tumor brain interface is demarcated (Figure 1C). Special precaution was taken not to violate the tumor brain interface towards the side of motor area marked by TMS.

Complete tumor resection was achieved in two and subtotal in three (Figure 1D). None of them developed any neurological deficit in the post

operative period. At 12 months follow up all of them were doing well.

## DISCUSSION

Resection of low grade glioma close to the motor strip area is difficult. Functional preservation necessitates the use of advanced imaging like

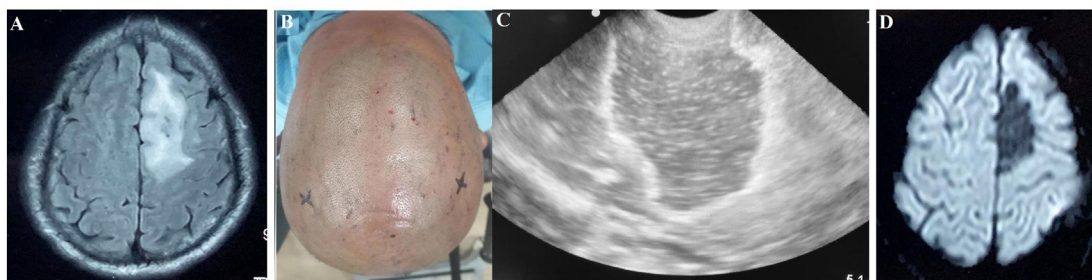


Figure 1. A: pre operative MRI (FLAIR) showing hyper intense lesion suggestive of LGG close to the motor cortex. B: Pre operative patient image showing the marked area for hand as stimulated through TMS. Note the marked area on left side is slightly posterior to right one. C: Intra operative 2DUSG showing tumor margin demarcated by water saline mixture. D: Post op MRI (FLAIR) showing resection of the tumor.

fMRI, diffusion tensor imaging, intra op mapping and direct electrical stimulation. But in their absence such surgeries would place the patient at risk for additional neurological deficit. Assessment of functional areas in the pre operative period with the use of TMS is well known.

Transcranial magnetic stimulation is a novel neuromodulation technique that uses magnetic pulses (stimuli) which gets converted to electrical stimuli on reaching the brain surface and produce focal cortical stimulation or inhibition. It has been used for investigational as well as therapeutic purposes for several neurological and psychiatric disorders over past several decades.<sup>3</sup>

TMS has been used as an investigational tool for motor mapping. Initial evidences suggest that TMS can be helpful as a tool to guide the neurosurgeons to plan for tumor resection.<sup>4</sup> Various factors like use of navigation system, motor state of individual during mapping, position of grids, type and intensity of stimulators and the muscle groups used for assessment may influence the outcome. These factors need to be considered while deciding the final result.<sup>4</sup>

TMS uses various parameters and techniques for motor mapping. The standard method uses the five centimeter localization method for identification of motor strip (hand area) and dorsolateral prefrontal cortex; however, neuronavigational techniques and Beam F3 method for localization of motor cortex and dorsolateral prefrontal cortex are increasingly used due to accuracy in localization.<sup>5,6</sup> Here, we used the conventional five-centimeter localization method to identify the displacement of motor strip for guidance for tumor resection. New innovative tools may guide clinicians to understand the neuroscience better and cross-disciplinary collaboration may strengthen the research in neuroscience.<sup>7</sup>

TMS is used in most of the centers for neuromodulation in the department of psychiatry. This can be utilized for pre operative identification of the motor area adjacent to the glioma. Again radiological identification of central sulcus is tricky in presence of peritumoral brain edema. Use of TMS would help to mark the motor area before surgery and provides an idea for making craniotomy and starting the tumor decompression. Again a 2D ultrasound which is available in all radiological centers can be utilized for identification of tumor brain interface. This is cheaper, easily available and simple to use. Use of saline with air mixture acts as a contrast agent lining the tumor resection margin and thus guides the surgeon to continuously get oriented

towards the tumor brain interface.<sup>1</sup> In the absence of advanced technologies, TMS could able to localize the motor area in relation to the tumor in all our patients. Again intra operative use of USG further provided information about the tumor margin to safe guard the peritumoral eloquent brain. In two patients we could able to achieve gross total and in three subtotal resections without any additional deficits. Usually the brain tumor interface is difficult to interpret towards the end of tumor resection owing to tumor cavity bleed, peritumoral brain edema. Again the echogenicity of glioma also determines the quality of USG imaging. In uniformly hyperechoic brain tumors, the brain tumor differentiation appears better and therefore easy to detect the residual lesion. Therefore complete excision of tumor may not be feasible in all cases with the use of intra op 2D USG.<sup>1</sup>

In resource scarce settings like India, where the clinical caseloads are high, a collaborative model holds a promise to work better. In the absence of facilities like functional neuroimaging and neuro-navigation, manual methods with the help of TMS may accurately help in identifying the specific brain areas like motor strip. TMS and 2D USG, being a relatively less expensive machines and is increasingly availability in the tertiary centers in India, can prove to be beneficial for the neurosurgeons.

In conclusion, TMS is an effective tool in pre operative localization of motor cortex in patients with perirolandic LGG. This along with low cost 2D USG can be utilized for function preservation surgery in these patients in resource limited areas.

## REFERENCES

1. Sahoo SK, Salunke P, Ahuja CK. Revisiting intraoperative 2D USG with saline-air mixture as contrast for resection of eloquent area glioma in resource-deficient countries. *J Neurosci Rural Pract* 2021;12(4):780-5. doi: 10.1055/s-0041-1736151.
2. Sahoo SK, Mohanty M, Emanee SYS, *et al.* Magnetic resonance tractography and intraoperative direct electrical stimulation in eloquent area glioma surgery for 102 cases: A tertiary care center experience from Northwest India. *World Neurosurg* 2023;172:e655-e666. doi: 10.1016/j.wneu.2023.01.113.
3. Lefaucheur JP, Aleman A, Baeken C, *et al.* Evidence-based guidelines on the therapeutic use of repetitive transcranial magnetic stimulation (rTMS): An update (2014–2018). *Clin Neurophysiol* 2020; 131(2):474-528. doi:10.1016/j.clinph.2019.11.002.
4. Sondergaard RE, Martino D, Kiss ZHT, Condliffe EG. TMS motor mapping methodology and reliability: A structured review. *Front Neurosci* 2021; 15:709368. doi:10.3389/fnins.2021.709368.

5. Ahdab R, Ayache SS, Brigoeres P, Goujon C, Lefaucheur JP. Comparison of “standard” and “navigated” procedures of TMS coil positioning over motor, premotor and prefrontal targets in patients with chronic pain and depression. *Neurophysiol Clin* 2010; 40(1):27-36. doi:10.1016/j.neucli.2010.01.001.
6. Trapp NT, Bruss J, Johnson MK, *et al.* Reliability of targeting methods in TMS for depression: Beam F3 vs. 5.5 cm. *Brain Stimul* 2020; 13(3):578-81. doi:10.1016/j.brs.2020.01.010.
7. Quaglio G, Corbetta M, Karapiperis T, *et al.* Understanding the brain through large, multidisciplinary research initiatives. *Lancet Neurol* 2017; 16(3):183-4. doi:10.1016/S1474-4422(17)30020-0.