

CASE REPORTS

Unilateral variant of nasogastric tube syndrome in a patient with stroke: A case report

Sung Il Hwang *MD*

Department of Rehabilitation Medicine, Soonchunhyang University Gumi Hospital, Gyeongsangbuk-do, Korea

Abstract

Nasogastric tube (NGT) is often used in the early stages of stroke for nutritional support. Nasogastric tube syndrome (NGTS) is a rare but a life-threatening disorder characterized by the triad of NGT insertion, throat pain and vocal cord palsy. A 67-year-old man was admitted for right basal ganglia and intraventricular hemorrhage. He had a history of diabetes mellitus and hypertension. After stereotactic cranial aspiration, NGT feeding was started. At 11 weeks after NGT intubation, he presented with an ambiguous sore throat and stridor. Right posterior cricoarytenoid inflammation and ipsilateral vocal cord palsy was identified through neck computed tomography (CT). Removal of the NGT, endotracheal intubation and intravenous ceftriaxone administration were performed. His symptoms resolved completely and did not recur until discharge. NGTS should be evaluated early in stroke patients with NGTs who present with sore throat and stridor. Increased awareness and early diagnosis of NGTS are important for appropriate management and prevention of progression to fatal clinical outcome.

Keywords: Nasogastric tube, dysphagia, vocal cord palsy, stroke, cricoarytenoid muscle

INTRODUCTION

In the early stages of stroke, patient's nutritional status could become worse because of poor oral intake or dysphagia. Consequently, nasogastric tube (NGT) feeding is often necessary for adequate nutritional support.¹ Unfortunately, complications related to NGT feeding occur in 75.2% of the patients, such as incorrect placement, pneumothorax, hiatus hernias, and gastrointestinal bleeding.² Infrequently, cases of a laryngeal injury due to NGT have been reported since 1939.³ It was first named as nasogastric tube syndrome (NGTS) by Sofferman *et al.* in 1990. It appears to be caused by pressure on surrounding structures by NGT, and occurs more frequently in patients with diabetes mellitus (DM) or immunocompromised condition.⁴ This study presents a case of a stroke patient with DM who developed a unilateral variant of NGTS.

CASE REPORT

A 67-year-old man with non-insulin dependent

DM and hypertension presented to the emergency room with altered mental status and left side weakness. Brain computed tomography (CT) showed an intracerebral hemorrhage (ICH) in the right basal ganglia and intraventricular hemorrhage. He was admitted to the department of neurosurgery, where he underwent stereotactic cranial aspiration. Five days later, NGT feeding was initiated. Although his neurologic status progressively improved, he developed a fever, and sputum culture identified *Enterobacter aerogenes*. After 16 days of intravenous (IV) meropenem, his general condition improved, and rehabilitation program was started. At 7 weeks, he was transferred to the department of rehabilitation medicine, where he underwent an intensive rehabilitation program. One week later, he was infected with COVID-19, and was treated with IV Remdesivir for three days and IV Piperacillin/Tazobactam for ten days. At 11 weeks after NGT insertion, he began to complain of a sore throat and occasional inspiratory stridor. However, he did not exhibit fever, dyspnea or oxygen desaturation. Two

Address correspondence to: Sung Il Hwang, Department of Rehabilitation Medicine, Soonchunhyang University Gumi Hospital, 179, Gongdan-ro, Gumi, Gyeongsangbuk-do, Korea. Tel: 082-054-468-9270, Email: rmhsi@schmc.ac.kr

Date of Submission: 19 April 2024; Date of Acceptance: 21 December 2024

<https://doi.org/10.54029/2025yhr>

days later, his symptoms worsened, with dyspnea and oxygen desaturation. The arterial blood gas analysis at room air revealed pH of 7.370, $p\text{CO}_2$ of 47.8 mmHg, $p\text{O}_2$ of 49.1 mmHg, and O_2 saturation 83.3%. Neck CT showed swelling of the right posterior cricoarytenoid muscle adjacent to the NGT, suggesting right vocal cord palsy (Figure 1). The NGT was removed, and endotracheal intubation was performed. Additionally, total parenteral nutrition and IV ceftriaxone 2g were started. Ten days later, his symptoms and inspiratory stridor improved, and a follow up neck CT revealed decrease swelling. Extubation was performed and ceftriaxone was stopped. Twenty days later, the NGT was reinserted and maintained until discharge.

DISCUSSION

NGTS was initially described by Soffer and Hubbell in 1981. It is a rare but life-threatening disorder characterized by NGT insertion, sore throat, and vocal cord paralysis, which is usually bilateral. The study proposed pathophysiological mechanisms for the development of NGTS include pressure exerted against the posterior cricoid lamina by the NGT, causing posterior cricoid ulceration and inflammation. This extends to the posterior cricoarytenoid muscles, and consequently bilateral vocal cord dysfunction occurs.^{4,5} Another study presented the case of laryngeal abductor muscle injury without

esophageal ulcer. It suggested that a laryngeal abductor muscle suffered circulatory damage because of the compression of the postcricoid blood vessel supplying the muscle.⁶

NGTS developed predominantly in male, and mostly in people over 60 years of age. Its exact cause remains uncertain, but DM and impaired immunity have been proposed as main risk factors.^{7,8} In this case, the patient's age (67-year-old), DM and poor general condition following COVID-19 may have contributed to the development of NGTS.

There are several studies investigating NGT-related factors associated with NGTS. It was reported that the duration of NGT use is not associated with the disorder. However, the positioning of the NGT within the esophagus appears to have a significant impact on the development of NGTS.⁸ Friedman *et al.* reported that although the rate of NGT midline positioning is only 6%, it can cause significant inflammation in the posterior cricoid area, leading to bilateral vocal cord palsy. In contrast, NGT lateral positioning induces less inflammation, and may not cause any symptoms, or result in a mild clinical course.

Sore throat is the most significant symptom suggesting NGTS. However, it occurs in only about 26%, and even then, it can be vague depending on the patient's level of awareness or ability to communicate as seen in the present case. Stridor or wheezing is more frequent, occurring in approximately 63%, and serves as an important sign of respiratory distress.^{6,8,10} Vocal cord palsy is usually bilateral, but hoarseness is not common.^{8,11} Asymptomatic NGTS has also been reported.¹²

Early diagnosis and management of NGTS is important because the disorder can progress rapidly to life-threatening respiratory distress. When NGTS is suspected, laryngoscopy should be performed immediately to identify ulceration of postcricoid area and/or vocal cord palsy. In addition, Neck USG/CT could be performed to confirm compressive pathologies.⁷ In this case, laryngoscopy was not done initially because NGTS was not considered. Instead, right vocal cord palsy was identified during endotracheal intubation. Furthermore, the neck CT study showed ipsilateral posterior arytenoid inflammation, and therefore could rule out neurogenic vocal cord palsy which may be due to recurrent stroke or COVID-19.¹³

The most important first step is to remove NGT. Tracheostomy or endotracheal intubation is usually needed, especially in cases of severe respiratory distress. Tracheostomy is more frequently performed because it may take a

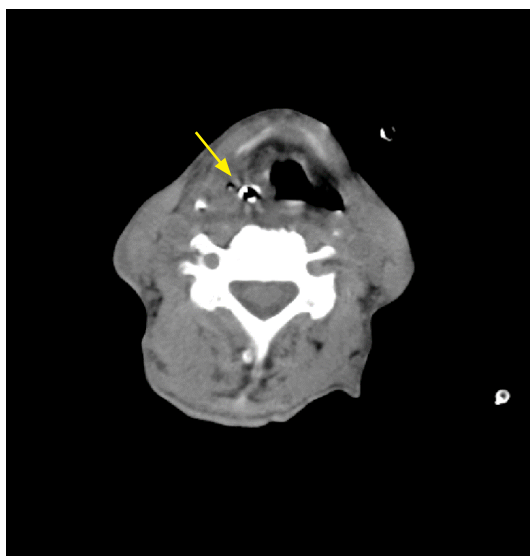


Figure 1. Computed tomography scan of the neck shows swelling and inflammation around the nasogastric tube (yellow arrow) in right posterior cricoarytenoid area.

longer time to improve vocal cord palsy after endotracheal intubation. Intravenous antibiotic therapy is necessary for the prevention of abscess. The prognosis is favorable if treated appropriately. 85% of patients improved clinically, and 35% of them recovered within five weeks.^{7,8} As observed in the present case of unilateral cricoarytenoid involvement, respiratory distress can be managed without tracheostomy.⁴

In conclusion, the potential for developing NGTS should be considered in a patient with NGT during subacute phase of stroke, especially in the diabetic or immunocompromised patient complaining of sore throat or stridor. Awareness of the NGTS can facilitate early diagnosis and treatment, thereby preventing life-threatening respiratory failure.

DISCLOSURE

Financial support: None

Conflict of interest: None

REFERENCES

1. Ojo O, Brooke J. The use of enteral nutrition in the management of stroke. *Nutrients* 2016; 8:827-32. <https://doi.org/10.3390/nu8120827>.
2. Rabaut J, Thirugnanachandran T, Singhal S, et al. Clinical outcomes and patient safety of nasogastric tube in acute stroke patients. *Dysphagia* 2022; 37:1732-9. <https://doi.org/10.1007/s00455-022-10437-1>.
3. Iglauer S., Molt W.F. Molt. LXXI severe injury to the larynx resulting from the indwelling duodenal tube. *Ann Otol Rhinol Laryngol* 1939; 48:886-904. <https://doi.org/10.1177/000348943904800402>.
4. Sofferan RA, Haisch CE, Kirchner JA, Hardin NJ. The nasogastric tube syndrome. *Laryngoscope* 1990; 100:962-8. <https://doi.org/10.1288/00005537-199009000-00010>.
5. Sofferan RA, Hubbell RN. Laryngeal complications of nasogastric tubes. *Ann Otol Rhinol Laryngol* 1981; 90:465-8. <https://doi.org/10.1177/000348948109000510>.
6. Isozaki E, Tobisawa S, Naito R, Mizutani T, Hayashi H. A variant form of nasogastric tube syndrome. *Intern Med* 2005; 44:1286-90. <https://doi.org/10.2169/internalmedicine.44.1286>.
7. Brousseau VJ, Kost KM. A rare but serious entity: nasogastric tube syndrome. *Otolaryngol Head Neck Surg* 2006; 135:677-9. <https://doi.org/10.1016/j.otohns.2006.02.039>.
8. Juneja D, Nasa P, Chanchalani G, Jain R. Nasogastric tube syndrome: A Meta-summary of case reports. *World J Clin Cases* 2024; 12:119-29. <https://doi.org/10.12998/wjcc.v12.i1.119>.
9. Friedman M, Baim H, Shelton V, et al. Laryngeal injuries secondary to nasogastric tubes. *Ann Otol Rhinol Laryngol* 1981; 90:469-74. <https://doi.org/10.1177/000348948109000511>.
10. Paul T, Shdid RKA, Khan SHU. Unilateral variant of NGT syndrome: An uncommon complication of a very common intervention. *Gerontol Geriatr Med* 2023; 9:1-5. <https://doi.org/10.1177/23337214231172626>.
11. Apostolakis LW, Funk GF, Urdaneta LF, McCulloch TM, Jeyapalan MM. The nasogastric tube syndrome: two case reports and review of the literature. *Head Neck* 2001; 23:59-63. [https://doi.org/10.1002/1097-0347\(200101\)23:1<59::aid-hed9>3.0.co;2-a](https://doi.org/10.1002/1097-0347(200101)23:1<59::aid-hed9>3.0.co;2-a).
12. Nehru VI, Al Shammari HJ, Jaffer AM. Nasogastric tube syndrome: the unilateral variant. *Med Princ Pract* 2003; 12:44-6. <https://doi.org/10.1159/000068162>.
13. Korkmaz MÖ, Güven M. Unilateral vocal cord paralysis case related to COVID-19. *SN Compr Clin Med* 2021; 3:2319-21. <https://doi.org/10.1007/s42399-021-01024-w>.